CENTRAL NERVOUS SYSTEM.

BRAIN—No. 16.

DISSECTION FROM THE OUTER SIDE OF THE LEFT CEREBRAL HEMISPHERE TO SHOW CERTAIN TRACTS OF LONG ASSOCIATION FIBRES.

The grey matter of the cortex with the short association fibres has been removed.

Association fibres connect different regions of the cortex of the same hemisphere. **Short association fibres** unite contiguous convolutions, and such as are removed only a short distance from one another.

Long association fibres are gathered together into fasciculi which lie in the white substance of the hemisphere, and connect areas of the cortex separated by considerable intervals.

The **superior longitudinal fasciculus** lies on the outer side of the corona radiata in the base of the fronto-parietal operculum. From the frontal lobe it extends backwards above the island of Reil and the lenticular nucleus to the posterior end of the fissure of Sylvius. Here many fibres radiate backwards into the occipital lobe, while the majority arch round the fissure of Sylvius, downwards and forwards into the temporal lobe.

The **inferior longitudinal fasciculus** lies on the outer side of the optic radiation. It extends from the posterior end of the occipital lobe to the anterior end of the temporal lobe.

The **fasciculus uncinatus** arches round the stem of the fissure of Sylvius, and connects the frontal pole and the orbital convolutions with the anterior part of the temporal lobe.

The figures indicate—

1. Superior longitudinal fasciculus.
2. Some of its occipital fibres.
3. Its temporal fibres.
4. Inferior longitudinal fasciculus. Some of it has been removed along with underlying fibres of the optic radiation, to show the Tapetum forming the outer wall of the posterior horn of the lateral ventricle.
5. Fasciculus uncinatus.
6. Fibres of the optic radiation above the roof of the descending horn of the lateral ventricle.
7. Outer wall of posterior horn.
8. White matter of the island of Reil with grey matter of claustrum showing through.
9. Temporal pole.
10. Internal orbital gyrus.

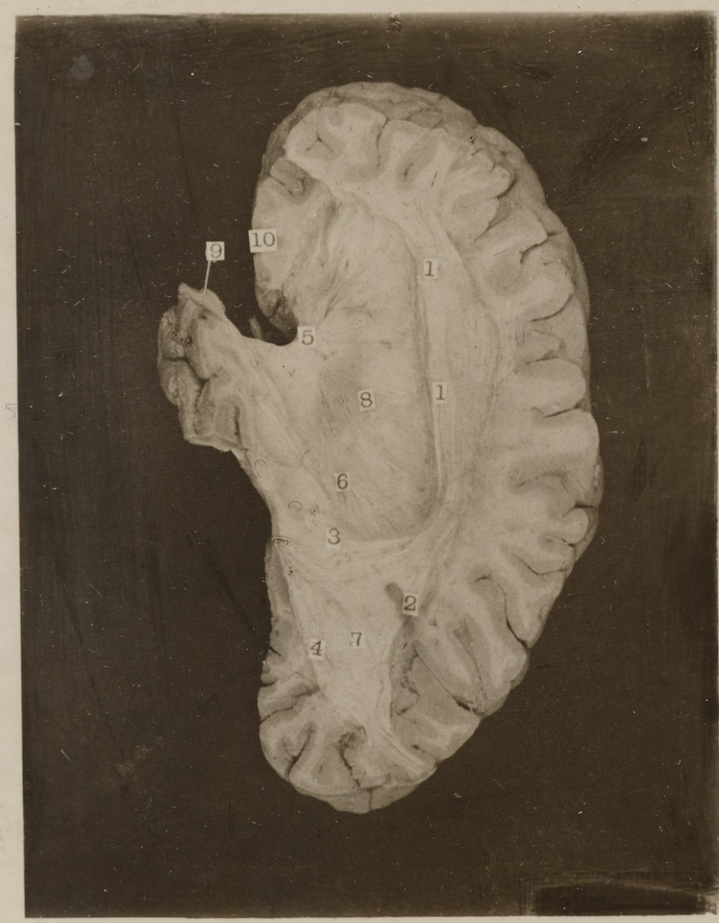

CENTRAL NERVOUS SYSTEM—BRAIN. No. 16.
(EDINBURGH STEREOSCOPIC ANATOMY)

Copyright: T. C. & E. C. Jack, Edinburgh, & 34 Henrietta Street, London, W.C.

(PHILCO CO.)