CRANIO-CEREBRAL TOPOGRAPHY—No. 8.

A COMPOSITE VIEW HAS BEEN TAKEN TO SHOW THE RELATION OF THE STRUCTURES SHOWN IN THE FORMER VIEW TO THE SURFACE MARKINGS.

While the parts shown here are largely inaccessible to surgical interference, the view shows the parts which may be injured, for instance, by a penetrating wound, or by a bullet entering the head at any particular point upon the surface. Among the relations shown, it may be mentioned that the **corpus callosum**, for example, extends both in front of and behind the area marked upon the surface as the Rolandic area, and that the upper margin of the third ventricle extends as far up as to the oblique line which indicated upon the surface the posterior horizontal limb of the Sylvian fissure.

The Gasserian ganglion lies under the dura mater immediately in front of the point marked 7, and slightly to its outer side, and this view shows the depth at which that point lies from the surface of the head.

The figures indicate—

1. Falx cerebri.
2. Tentorium cerebelli.
3. Lateral sinus.
4. Cerebral veins joining the superior longitudinal sinus.
5. Superior longitudinal sinus.
6. The corpus callosum.
7. Apex of the petrous temporal bone.
8. Fornix.
9. Anterior cerebral artery.
10. Optic chiasma.
11. Third ventricle.
12. Caudate nucleus in the floor of the lateral ventricle of the opposite side.

CRANIO—CEREBRAL TOPOGRAPHY. No. 8.

(EDINBURGH STEREOSCOPIC ANATOMY)
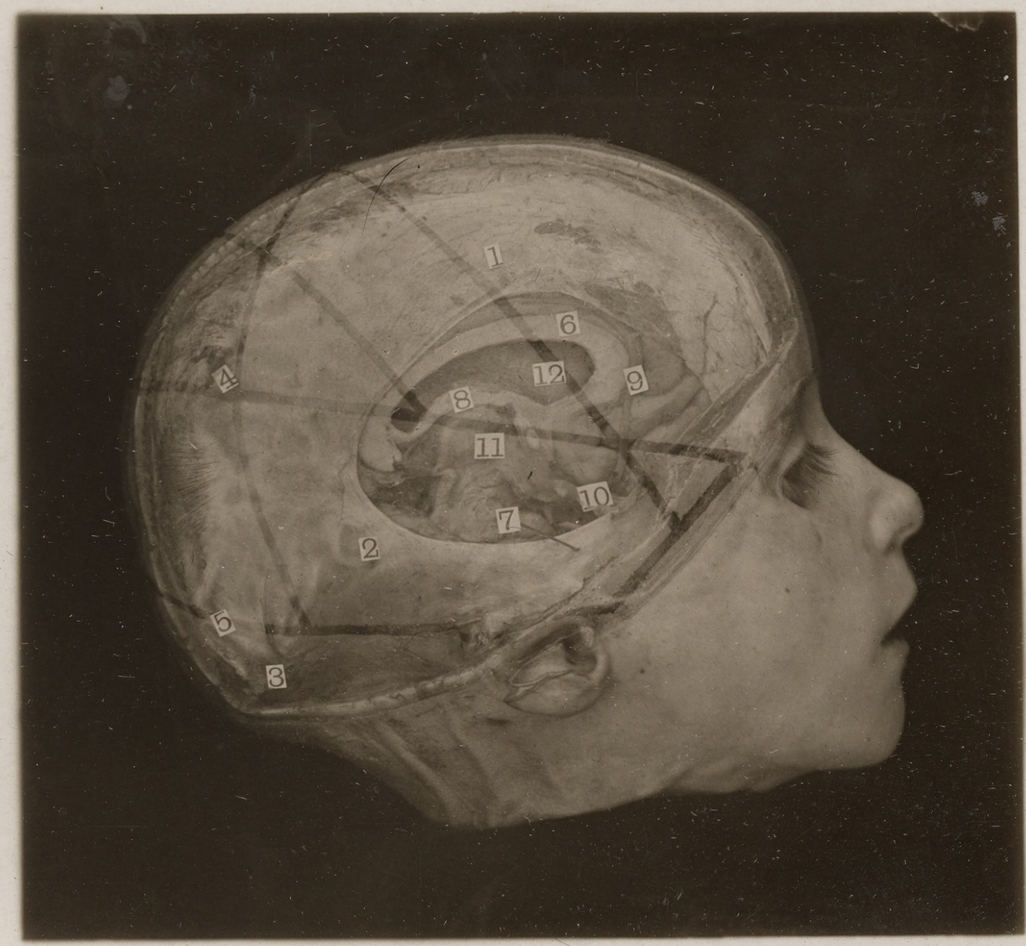
Copyright: T. C. & E. C. Jack, Edinburgh, & 34 Henrietta Street, London, W.C.