CRANIO-CEREBRAL TOPOGRAPHY—No. 1.

In localising different parts of the brain to the surface of the head certain definite bony points which can be recognised upon the surface constitute the primary landmarks, but as these points are few in number, they require to be supplemented by some arbitrary lines drawn between them, so as to fix certain points on the surface of the cranial vault.

The bony points which can be used are the following—

1. The **glabella,** a point midway between the superciliary ridges.
2. The **external occipital protuberance,** or **Inion.**
3. The **external angular process** of the frontal bone, which forms a protection at the outer and upper corner of the orbit.
4. The **root of the zygoma.** A point immediately above and in front of the external auditory meatus constitutes the **pre-auricular point.**
5. The **lambda,** the point of junction of the lambdoidal and sagittal sutures. It can usually be felt from the surface, and lies about 2½ inches above the external occipital protuberance.
6. The region of the **parietal eminence** is often distinct upon the surface.

The accessory guiding lines have been variously worked out, but the lines drawn here are in accordance with the method introduced by Professor Chiene and employed by Stiles in Cunningham's Textbook of Anatomy. They are determined as follows:—

The head being shaved, find in the mesial line of the skull between the glabella and the external occipital protuberance, the midpoint M, the three-quarter point T, and the seven-eighths point S. Find also the external angular process E, and the pre-auricular point P, and join EP, PS, and ET. Bisect EP and PS at N and R. Join MN and MR. Bisect also AB at C, and draw CD parallel to AM.

The letters indicate—

G.	Glabella.	P.	Root of zygoma.
M.	Midpoint between G and O.	N.	Midpoint between E and P.
D.	Upper end of a line parallel to AM.	R.	Midpoint between P and O.
T.	Three-quarter point between G and O.	A.	Intersection of MN and ET.
S.	Seven-eighths point between G and O.	C.	Midpoint between A and B.
O.	External occipital protuberance.	B.	Intersection of MR and ET.
E.	External angular process.		

CRANIO—CEREBRAL TOPOGRAPHY. No. 1.

(EDINBURGH STEREOSCOPIC ANATOMY)
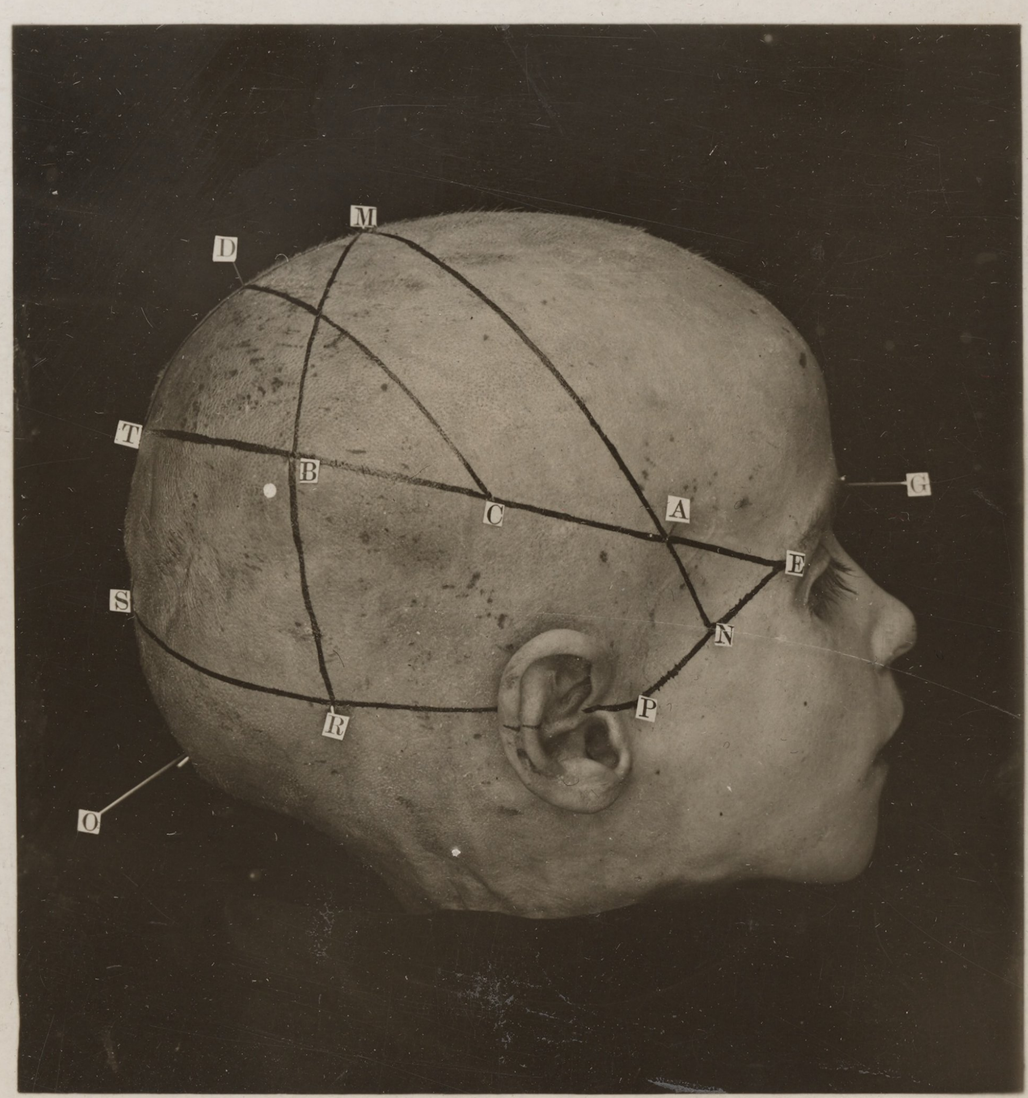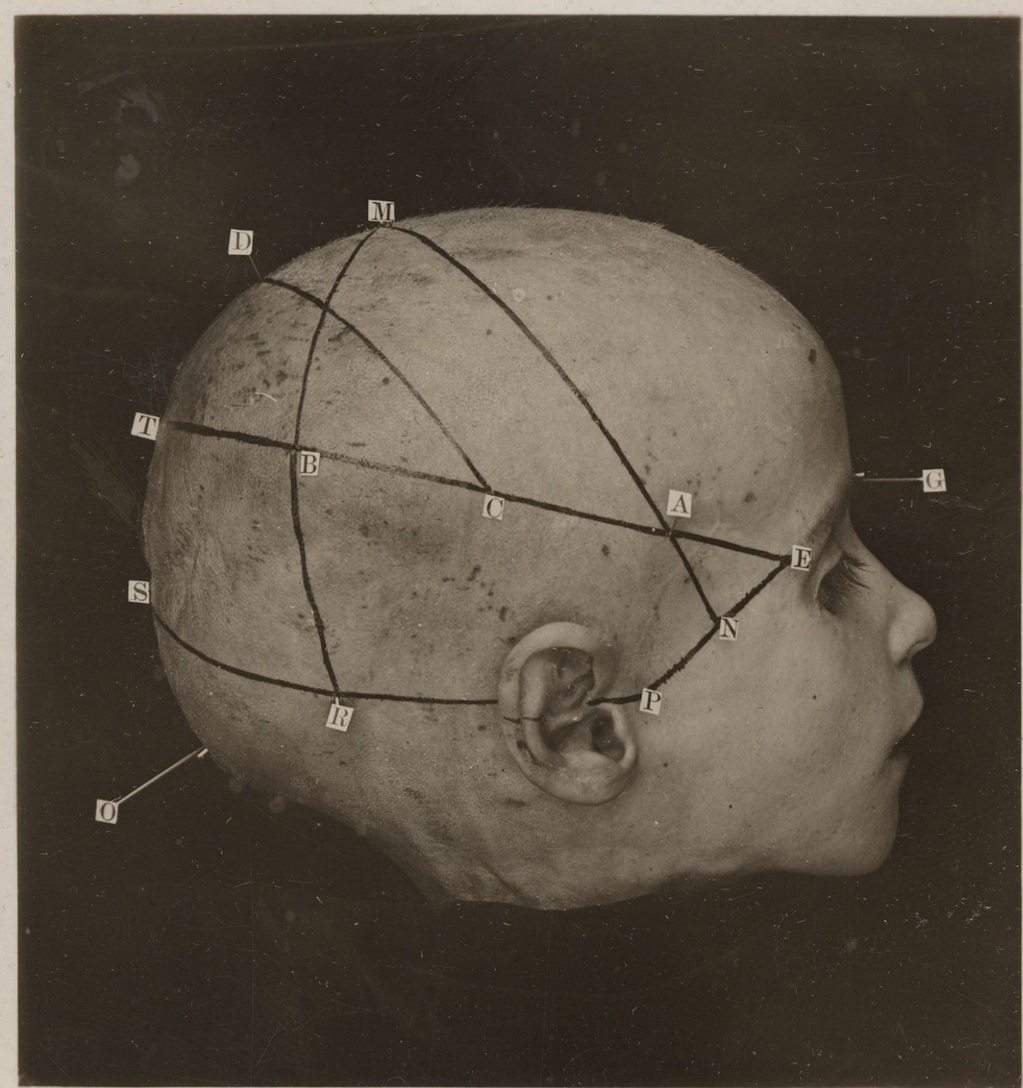
Copyright: T. C. & E. C. Jack, Edinburgh, & 34 Henrietta Street, London, W.C.