UPPER LIMB.

ANTECUBITAL FOSSA—No. 1.

THE SKIN AND SUPERFICIAL FASCIA HAVE BEEN REMOVED, LEAVING THE CUTANEOUS NERVES AND VESSELS IN SITU.

The antecubital fossa is a small hollow opposite the front of the elbow-joint bounded by muscles, and containing principally nerves and blood-vessels. Its roof is formed by skin and fasciæ, and contains the following structures :—

1. Nerves.—The cutaneous nerves in this region are derived from the internal and external cutaneous nerves. The former nerve pierces the deep fascia about the centre of the upper arm. Two branches, anterior and posterior, pass from it, and supply the front and inner side of the forearm. The branches pass, some over and some under the median basilic vein. The external cutaneous nerve,—the terminal branch of the musculo-cutaneous nerve,—becomes cutaneous at the outer border of the tendon of the biceps, and supplies the front and outer side of the forearm.

2. Veins.—The arrangement of the superficial veins in this region is very variable. There is, however, almost constantly, a large median basilic vein, which passes obliquely upwards and inwards from the centre of the antecubital fossa, and this is the vessel from which blood may be withdrawn in phlebotomy, or into which fluid may be transfused.

Its course and relations are therefore of interest, and it is formed in the following manner :—

The median vein passes up the centre of the forearm, and receives a tributary called the profunda vein. It then divides into two branches, the outer, usually smaller, is the median cephalic, and the inner is the median basilic vein. This latter trunk is joined by one or two ulnar branches, and the resulting vessel is the basilic, while the median cephalic is joined by a radial vein and is then called the cephalic.

3. Lymphatic glands.—Two small lymphatic glands are seen lying in the superficial fascia just above the inner condyle. These glands receive lymphatic vessels from the forearm and hand.

The figures indicate—

Veins—1. Median.
2. Median cephalic.
3. Median basilic.
4. Anterior ulnar.
5. Basilic.

Veins—6. Posterior ulnar.
Nerves—7. Internal cutaneous.
8. Musculo- or external cutaneous.
Glands—9. Epitrochlear lymphatic glands (two).

EDINBURGH: T. C. & E. C. JACK; AND 34 HENRIETTA STREET, LONDON, W.C.

UPPER LIMB—ANTECUBITAL FOSSA. No. 1.
(EDINBURGH STEREOSCOPIC ANATOMY.)
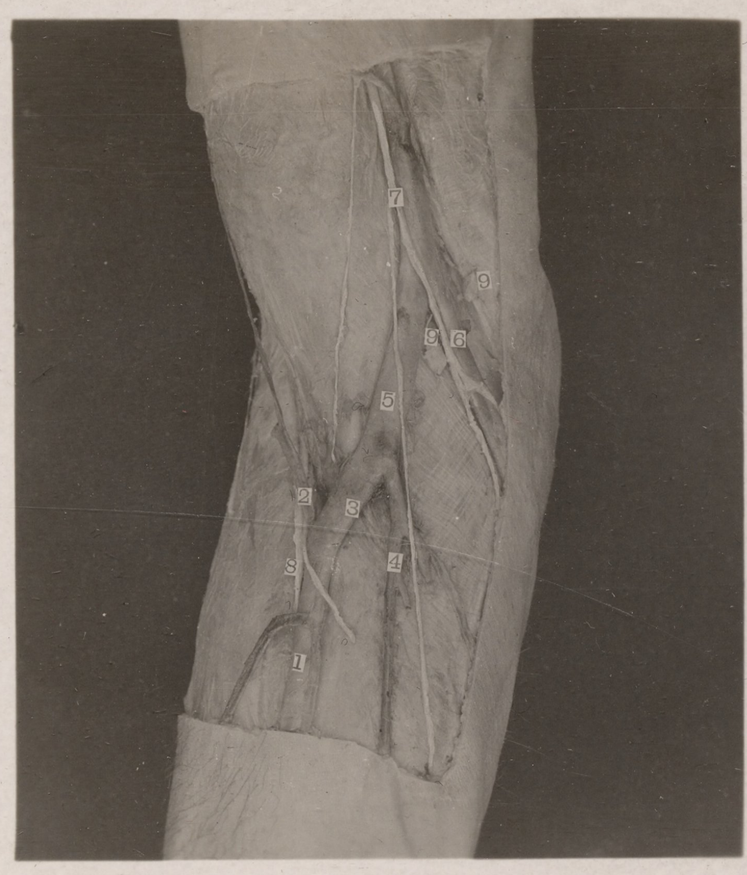
Copyright: T. C. & E. C. Jack, Edinburgh, & 34 Henrietta St., London, W.C.