UPPER LIMB.

AXILLA—No. 1.

THE SKIN AND FASCIÆ HAVE BEEN REMOVED, LEAVING THE CENTRAL PORTION OF THE AXILLARY, OR DEEP FASCIA, TO SHOW ITS CONNECTIONS, AND TO SHOW THE SUPERFICIAL NERVES, ETC., WHICH PASS DOWN THE ARM.

The **axillary fascia** is strong and thick, and forms the floor of the axillary space. It is continuous with the deep fascia of adjacent regions, passing, in front, on to the pectoralis major, on the inner side to the serratus magnus, behind, to the latissimus dorsi and teres major muscles, while on the outer side, it is in continuity with the general fascial investment of the upper arm. As it is connected by areolar tissue to the structures of the interior of the axillary space, it is drawn up, and forms the distinct fossa seen here.

It is pierced by some small cutaneous vessels and nerves. This fascia limits any swellings, especially fluid ones, which may occur in the axilla, and resists the spread of such to the surface.

It requires to be divided in opening axillary abscesses, and this is best done by Hilton's method, using a blunt instrument.

The structures which pass from the axilla down the upper arm are shown as seen by removal of a portion of the deep fascia. Of these, the axillary vein should always be identified first of all. It lies immediately subjacent to the deep fascia, and, when distended, overlaps and conceals the artery and some of the nerves.

Along the inner side of the vein is found the lesser internal cutaneous nerve, which unites in a variable manner with the lateral cutaneous branch of the second intercostal nerve, and with it runs down to supply the skin on the inner aspect of the arm as far as to the elbow.

Some branches of the lesser internal cutaneous nerve are seen running outwards on the coraco-brachialis and biceps.

The internal cutaneous nerve lies, in this region, to the outer side of the vein, and becomes cutaneous about the middle of the arm.

The figures indicate—

1. Anterior fold of axilla (pectoralis major).
2. Inner wall ,, ,, (serratus magnus).
3. Posterior wall ,, (latissimus dorsi).
4. Coraco-brachialis muscle.
5. Biceps muscle, short head.
6. Triceps muscle, long head.
7. Axillary vein.
8. Axillary artery.
9. Axillary fascia.

EDINBURGH: T. C. & E. C. JACK; AND 34 HENRIETTA STREET, LONDON, W.C.

UPPER LIMB—AXILLA. No. 1.

(EDINBURGH STEREOSCOPIC ANATOMY.)

Copyright: T. C. & E. C. Jack, Edinburgh, & 34 Henrietta St., London, W.C.

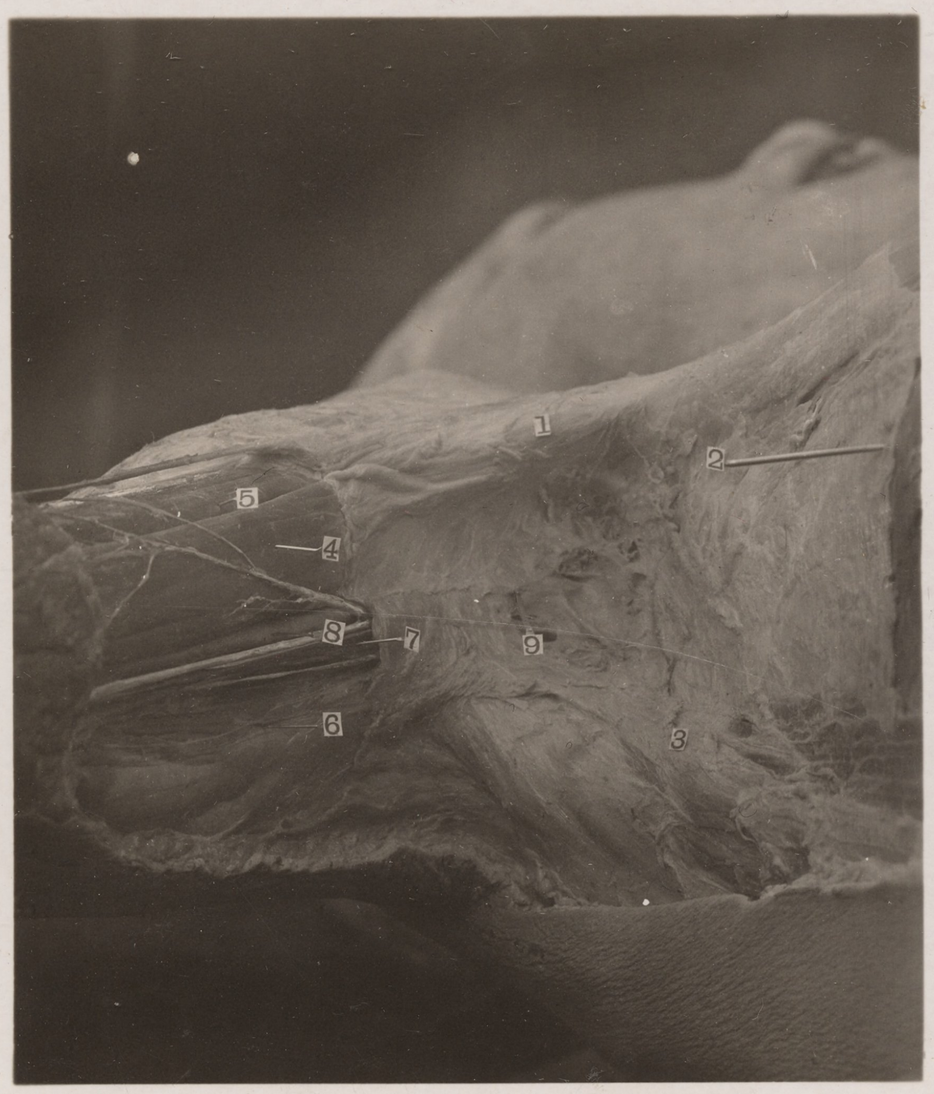

ROTARY PHOTO. E.C.