UPPER LIMB.

SURFACE ANATOMY—No. 3.

UPPER PART OF THE BACK.

The spines of the vertebræ lie at the bottom of a furrow between the erector spinæ and other muscles on each side.

The spine of the vertebra prominens (seventh cervical) can usually be detected, but that of the first dorsal vertebra immediately below it is often equally distinct. The other dorsal spines can only be distinguished with difficulty.

The outline of the scapula is obscured by muscles covering it, but the lower angle can be made out by palpation, and the spine and acromion process can also be readily felt. About the scapula itself there are several hollows and elevations, which vary very considerably in different individuals on account of the varying sizes of different muscles.

The upper margin of the trapezius slopes outwards from the neck to the clavicle (4) and some of its fleshy fibres below this level form an elevation just above the spine of the scapula (1).

When the arms are in the attitude shown here, the scapula is rotated, so that the inner end of the spine is displaced downwards, and the lower angle of the bone rotated outwards. This accounts for the apparently low position of the spine of the scapula. Below the spine is seen a rounded elevation showing the position of the rhomboideus major muscle. The root of the spine of the scapula usually lies at the level of the second dorsal vertebra, and the lower angle of the scapula extends down to the seventh rib. The 'triangle of auscultation' lies to the inner side of this lower angle.

The figures indicate—

1. Trapezius muscle.
2. Vertebra prominens.
3. Spine of scapula.
4. Upper margin of trapezius.
5. Deltoid muscle.
6. Rhomboideus major muscle.
7. Acromion process.

EDINBURGH: T. C. & E. C. JACK; AND 34 HENRIETTA STREET, LONDON, W.C.

UPPER LIMB—SURFACE ANATOMY. No. 3.

(EDINBURGH STEREOSCOPIC ANATOMY.)

Copyright: T. C. & E. C. Jack, Edinburgh, & 34 Henrietta St., London, W.C.

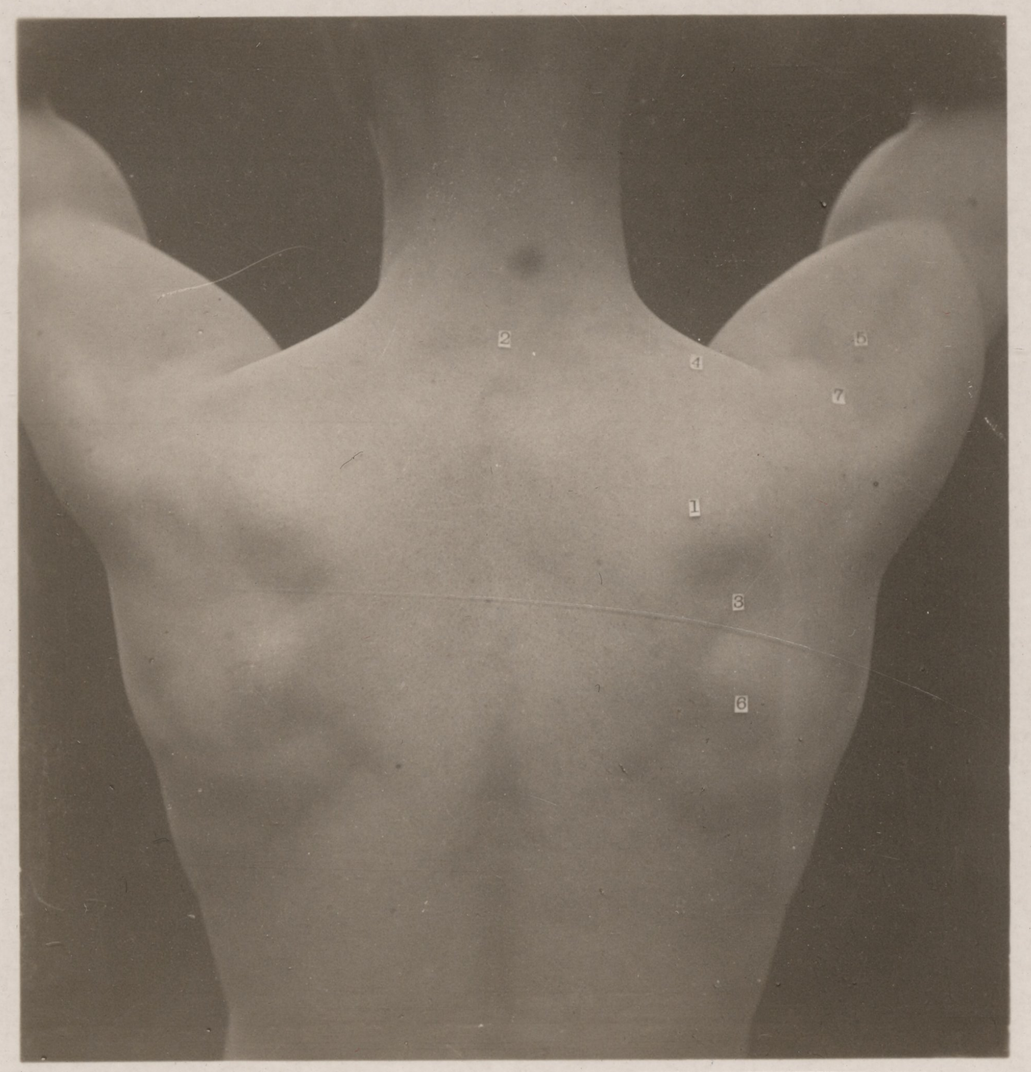

ROTARY PHOTO. E.C.