# THORAX.

## BACK—No. 5.

THE STRUCTURES SEEN IN THE PRECEDING VIEW ARE SHOWN IN TOPOGRAPHICAL RELATION TO THE SPINE AND THE RIBS.

The surface relationships seen here are numerous and important.

**Heart.** The heart extends from between the fifth and sixth dorsal spines above down to the ninth dorsal spine below, but the basal surface, *i.e.* as far down as to the auriculo-ventricular groove, extends only to the eighth dorsal spine. The apex of the heart lies in front of the ninth rib below the lower angle of the scapula, and slightly internal to it.

**Trachea.** The lower margin of the bifurcation of the trachea lies in front of the spine of the fifth dorsal vertebra, and the roots of the lungs, which are of considerable vertical extent, lie in front of the fifth, sixth, and seventh dorsal spines.

**Stomach.** The cardiac orifice of the stomach lies at the level of the tenth dorsal spine, while the fundus passes upwards almost to the spine of the ninth dorsal vertebra.

The splenic flexure of the colon and the tail of the pancreas come to lie under cover of the eleventh rib.

Very considerable differences exist between the statements made in different text books as to the level of the above structures in relation to the spines of the vertebræ.

The bifurcation of the trachea, *e.g.* is often said to be at the level of the third dorsal spine. The bifurcation is certainly at a lower level than that in this specimen. The level of the other structures may be taken as being fairly typical, but apparently considerable individual variations may be found.

---

***The large numbers rest upon corresponding dorsal and lumbar spines.***
***The small numbers indicate—***

1. Aortic arch.
2. Œsophagus.
3. Right bronchus.
4. Left bronchus.
5. Vena azygos major.
6. Left pulmonary artery.
7. Pericardium, divided.
8. Right vagus nerve.
9. Constriction on œsophagus.
10. Fundus of stomach.
11. Tail of pancreas.
12. Splenic vessels.
13. Descending colon.
14. Diaphragm.
15. Auriculo-ventricular sulcus.
16. Œsophagus.
17. Ampulla phrenica.
18. Inferior vena cava.
19. Bifurcation of trachea.
20. Commencement of abdominal aorta.

EDINBURGH: T. C. & E. C. JACK: AND 34 HENRIETTA STREET, LONDON, W.C.

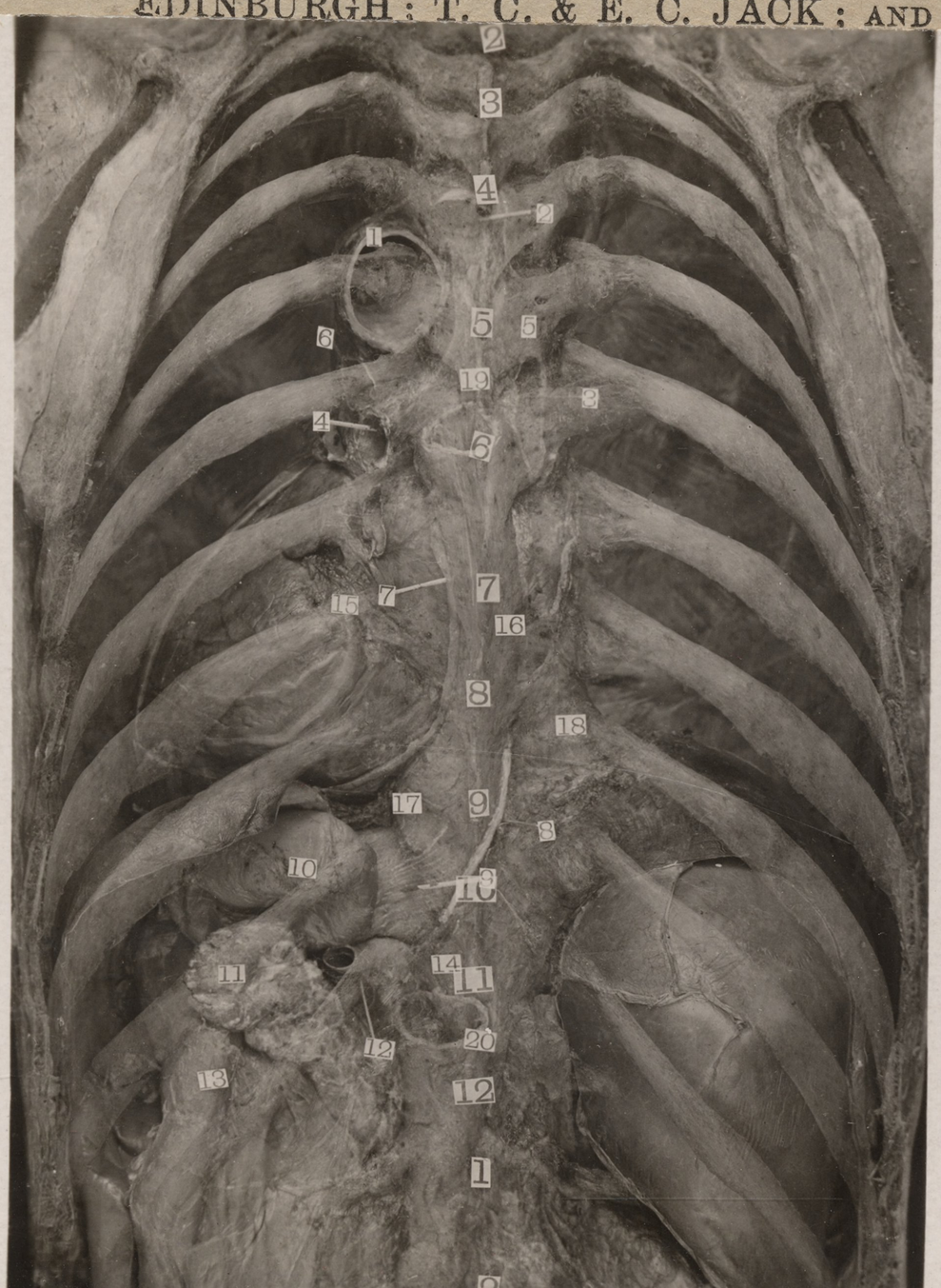


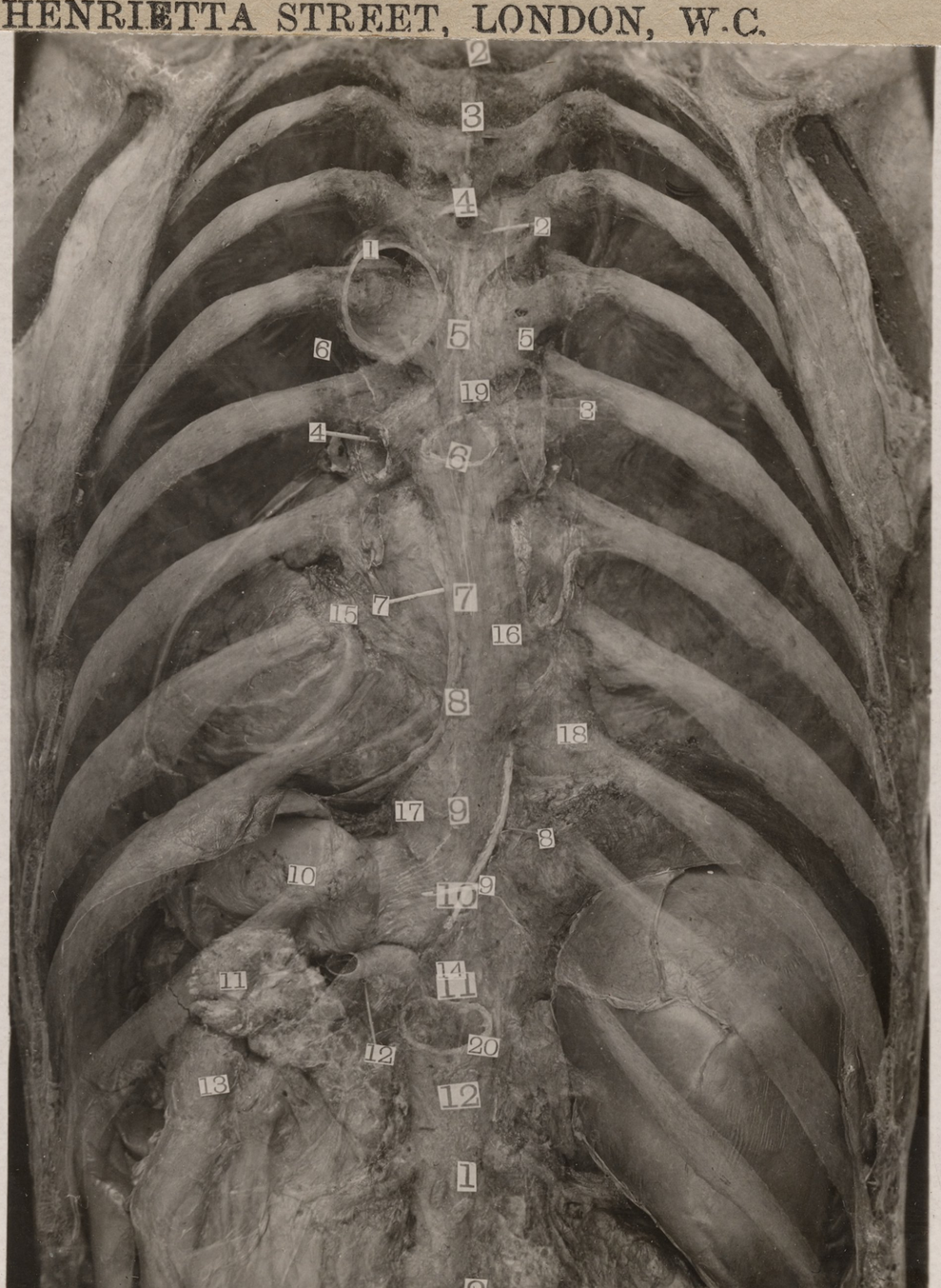


THORAX—BACK. No. 5.
(EDINBURGH STEREOSCOPIC ANATOMY.)
Copyright: T. C. & E. C. Jack, Edinburgh, & 34 Henrietta St., London, W.C.