THORAX.

HEART and PERICARDIUM—No. 1.

TWO SPECIMENS VIEWED FROM IN FRONT.

A. The heart, great vessels, and trachea have been removed from the body in one piece, and the front of the pericardium removed.

The characteristic, somewhat quadrilateral shape of the antero-superior surface of the heart, subdivided by the auriculo-ventricular and interventricular furrows, is well seen. This surface is composed of the ventricles mainly, but the right auricular appendix and the tip of the left auricular appendix also come into it. Above the heart itself, three great vessels lie nearly vertically side by side, the superior vena cava, the ascending aorta, and the pulmonary artery, flanked on either side by the auricular appendix.

The prominence of the right ventricle from which the pulmonary artery springs is very distinct.

B. The heart, enclosed in pericardium has been removed, with the aortic arch, and the thymus gland.

The size of the thymus in this view (also from an adult) is noticeable.

The figures indicate—

In both Specimens.—

1. Superior vena cava.
2. Innominate artery.
3. Left common carotid artery.
4. Left subclavian artery.
5. Ascending aorta.
6. Pulmonary artery.

In A:—

7. Ligamentum arteriosum.
8. Right auricular appendix.
9. Anterior interventricular furrow.

EDINBURGH: T. C. & E. C. JACK; AND 34 HENRIETTA STREET, LONDON, W.C.

THORAX—HEART & PERICARDIUM. No. 1.
(EDINBURGH STEREOSCOPIC ANATOMY)

Copyright: T. C. & E. C. JACK, Edinburgh, & 34 Henrietta St., London, W.C.

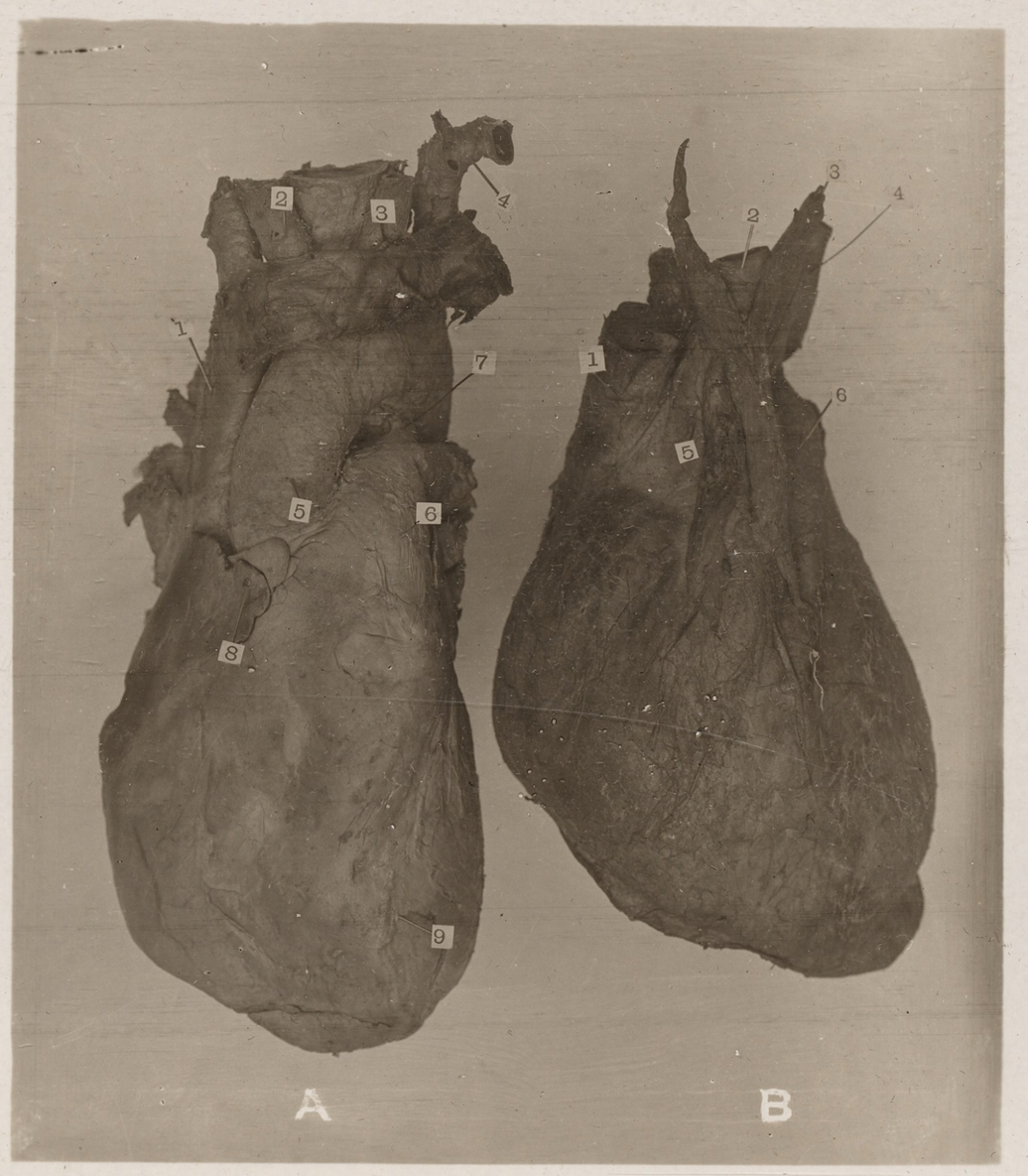

ROTARY PHOTO. E.C