THORAX.

MEDIASTINA—No. 5.

SUPERIOR MEDIASTINUM AND UPPER PORTIONS OF THE PLEURAL MEMBRANES VIEWED FROM THE FRONT.

After exposure of the superior mediastinum, the thymus and lymphatic glands, the innominate veins, and the superior vena cava have been removed.

The aortic arch and the branches rising from it are seen in their relation to the trachea and pleura. The root of the left common carotid artery is here united with the innominate artery, a fairly common variation from the normal arrangement.

The vessels and nerves in relation to the pleura are well seen, and especially the course of the phrenic and vagi nerves. The vagi sink backwards to reach the posterior aspect of the roots of the lungs, while the phrenics pass down on an anterior plane.

The distended veins at the root of the neck are seen to be of formidable size.

The figures indicate—

1. Upper limit of serous pericardium.
2. Aortic arch.
3. Innominate artery.
4. Left common carotid artery.
5. Left subclavian artery.
6. Right common carotid artery.
7. Right subclavian artery.
8. Internal jugular veins.
9. Subclavian veins, receiving external jugular and transversalis colli veins.
10. Pleura.
11. Right internal mammary artery and phrenic nerve.
12. Vagus nerves, the right giving off its recurrent laryngeal branch, and the left lower down, a cardiac branch.
13. Isthmus of thyroid gland.
14. Trachea.
15. Vena azygos major, opening into the superior vena cava.

THORAX—MEDIASTINA. No. 5.
(EDINBURGH STEREOSCOPIC ANATOMY)
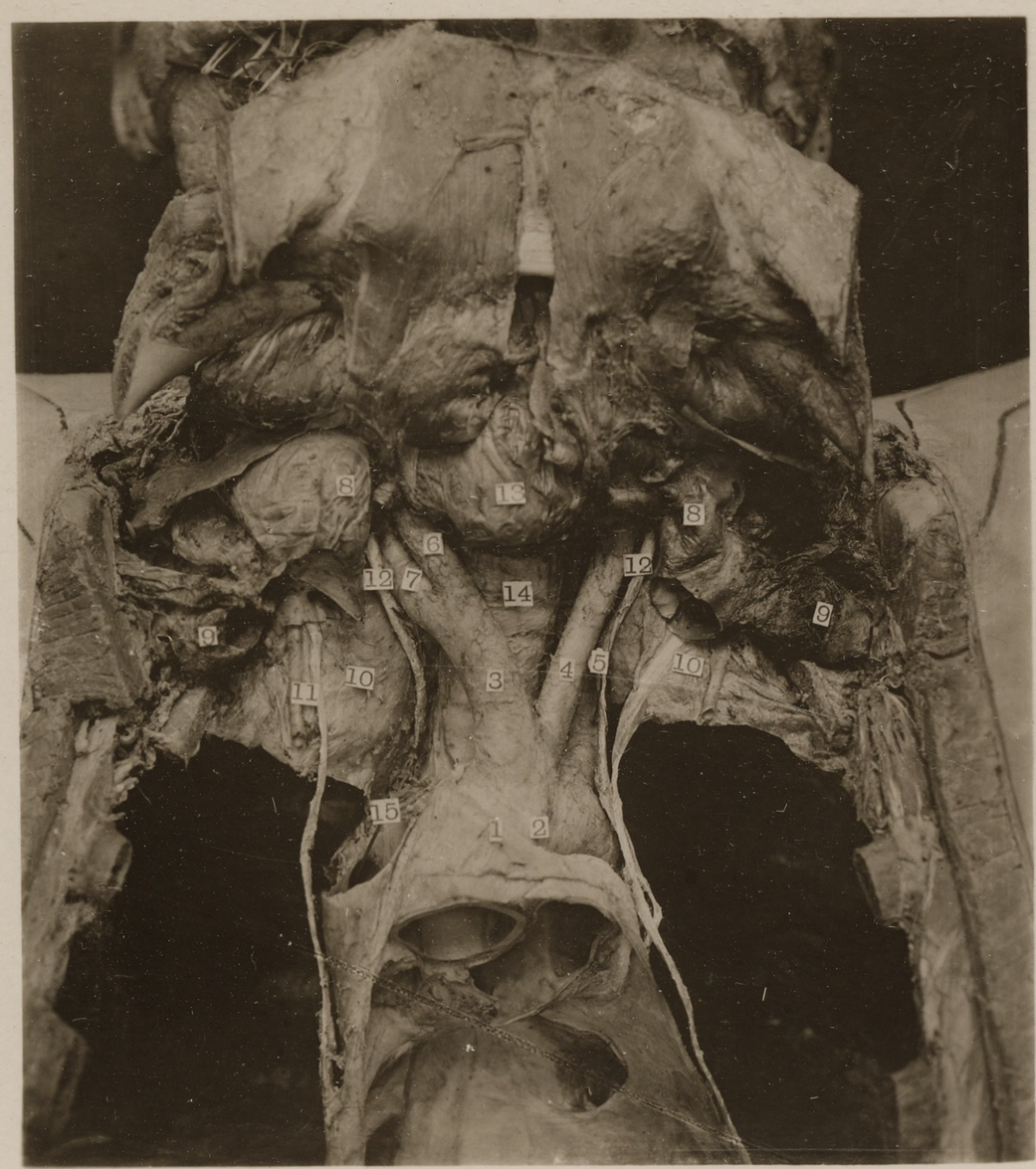
Copyright: T. C. & E. C. Jack, Edinburgh, & 34 Henrietta Street, London, W.C.