THORAX.

MEDIASTINA—No. 4.

THE SUPERIOR MEDIASTINUM VIEWED FROM THE FRONT.

The clavicles and first costal arches have been divided, and the manubrium sterni with the origins of the sterno-hyoid and sterno-thyroid muscles turned up, exposing the superior mediastinum.

The upper part of the thymus gland is seen in the form of two lobes lying on the left innominate vein—the lower part of the gland which lay in front of the pericardium has been removed.

The intimate relation of the innominate veins to the pleural membranes is well shown.

The thymic and inferior thyroid veins are large and form a plexus.

The attachments of the sterno-hyoid and sterno-thyroid muscles to the back of the manubrium are seen, and, between the sterno-thyroids, the interclavicular ligament.

The internal jugular veins become dilated just above their junction with the subclavian veins, forming the inferior jugular bulb.

The figures indicate—

1. Internal mammary artery lying on the pleura.
2. Left innominate vein, with thymus gland resting on it.
3. Right innominate vein.
4. Upper part of thymus gland (two lobes).
5. Isthmus of thyroid gland.
6. Left common carotid artery.
7. Innominate artery.
8. Right and left vagi, within the carotid sheaths.
9. Mediastinal lymphatic glands.
10. Inferior thyroid vein.
11. Sterno-thyroid muscle.
12. Sterno-hyoid muscle.

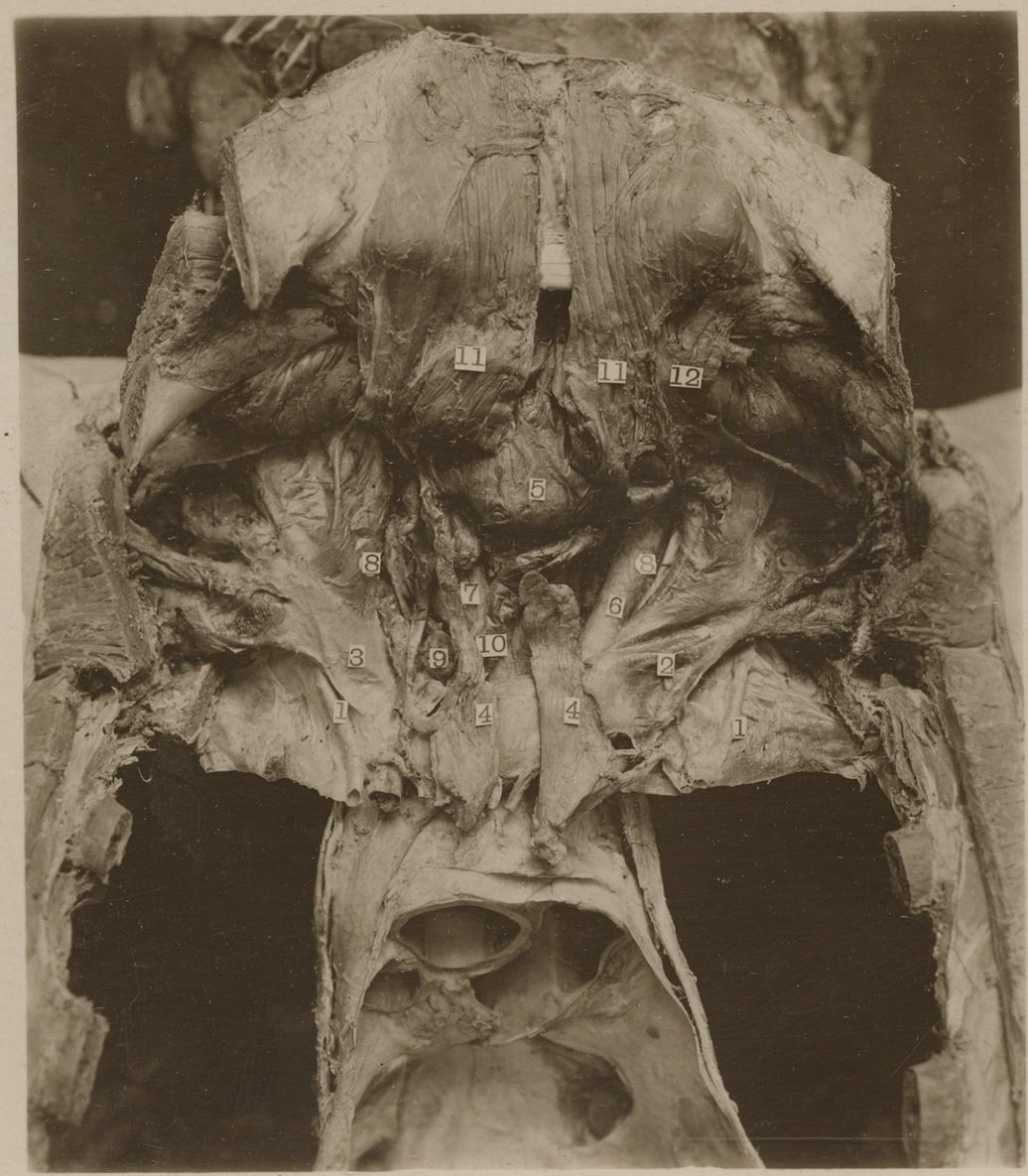

THORAX—MEDIASTINA. No. 4.

(EDINBURGH STEREOSCOPIC ANATOMY)

Copyright: T. C. & E. C. Jack, Edinburgh, & 34 Henrietta Street, London, W.C.