THORAX—No. 13.

INTERIOR OF THE VENTRICULAR CHAMBERS FROM THE FRONT.

The anterior wall of both the ventricles and of the right auricle has been removed, and also most of the interventricular septum, the infundibular cusp of the tricuspid valve, and the front of the right auriculo-ventricular ring. The pulmonary artery and the aorta have also been opened at their roots. This view illustrates clearly the wide interval which exists between the apertures leading to and from the right ventricle and also the close proximity to one another of the corresponding apertures of the left side.

In the right auricle some of the musculi pectinati are seen, but the tip of the auricular appendix which projected in front of the root of the aorta, and has left an impression there, has been removed.

In the right ventricle portions of the marginal and septal cusps are seen, and, in the left ventricle, the anterior or aortic cusp of the mitral valve, with the chordae tendineae and papillary muscle.

The segments of the aortic and pulmonary valves are arranged in an anterior and posterior set in each, in the pulmonary one segment is placed posteriorly (6), and in the aortic two, both of which are seen.

The figures indicate—

1. Pericardial reflection from pulmonary artery and aorta.
2. Where the superior vena cava enters the right auricle, and the position of the pericardial reflection from it.
3. Fossa ovalis.
4. Septal cusp of tricuspid valve.
5. Interventricular septum, and cut chordae tendineae of septal cusp.
6. Posterior cusp of pulmonary valve.
7. Anterior papillary muscle of left ventricle.
8. Anterior (aortic) cusp of mitral valve.
9. Cusps of aortic valve.

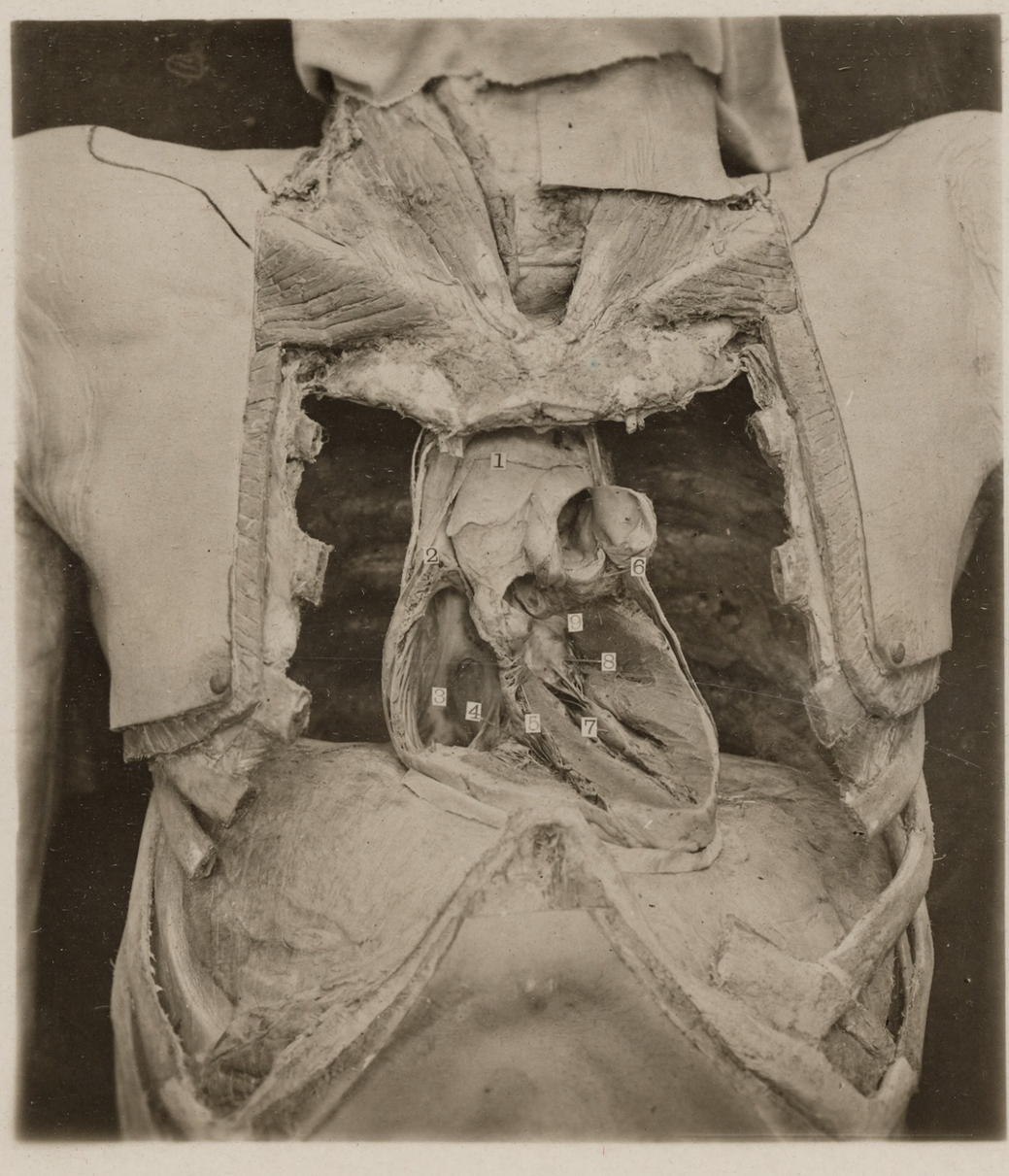

THORAX. No. 13.

(EDINBURGH STEREOSCOPIC ANATOMY)

Copyright: T. C. & E. C. Jack, Edinburgh, & 34 Henrietta Street, London, W.C.