ABDOMEN.

PELVIS—No. 8.

SAME AS NO. 7, AFTER REMOVAL OF THE BLADDER AND PROSTATE, AND OF THE ANTERIOR WALL OF THE ANAL CANAL.

I. *Anal Canal.* In the wall of the anal canal are seen (1) the *internal sphincter,* formed by a thickening of the circular muscle fibres of the intestine, (2) the *fibres of the levator ani,* and (3) externally, the *external sphincter.* In the interior can be seen one of the vertical folds of mucous membrane, or columns of Morgagni.

II. *Rectum.* The lateral flexions of the rectum are seen, they are usually three in number, two to left and one to the right, and at these bends a fold of mucous membrane projects into the interior of the canal, forming a rectal valve.

On each side of the rectum at the back is the para-rectal peritoneal fossa, and the peritoneum as it passes forwards on the rectum is seen to pass off first from the lateral and then from the anterior surface.

The figures indicate—

1. Levator ani muscle.
2. Obturator internus.
3. Internal sphincter.
4. Column of Morgagni in the anal canal.
5. Flexure of the rectum to the right.
6, 7. Apex of the ischio-rectal fossa, with internal pudic vessels and nerve, and a branch from the nerve to the levator ani.
8. Pelvic colon.
9. Pelvic vessels and nerves.
10. Obturator vessels and nerves.
11. Ureter.
12. External iliac vessels and genito-crural nerve.
13. Termination of the ileum.
14. Below the anterior crural nerve.
15. Commencement of the rectum.

ABDOMEN—PELVIS. No. 8

(EDINBURGH STEREOSCOPIC ANATOMY)
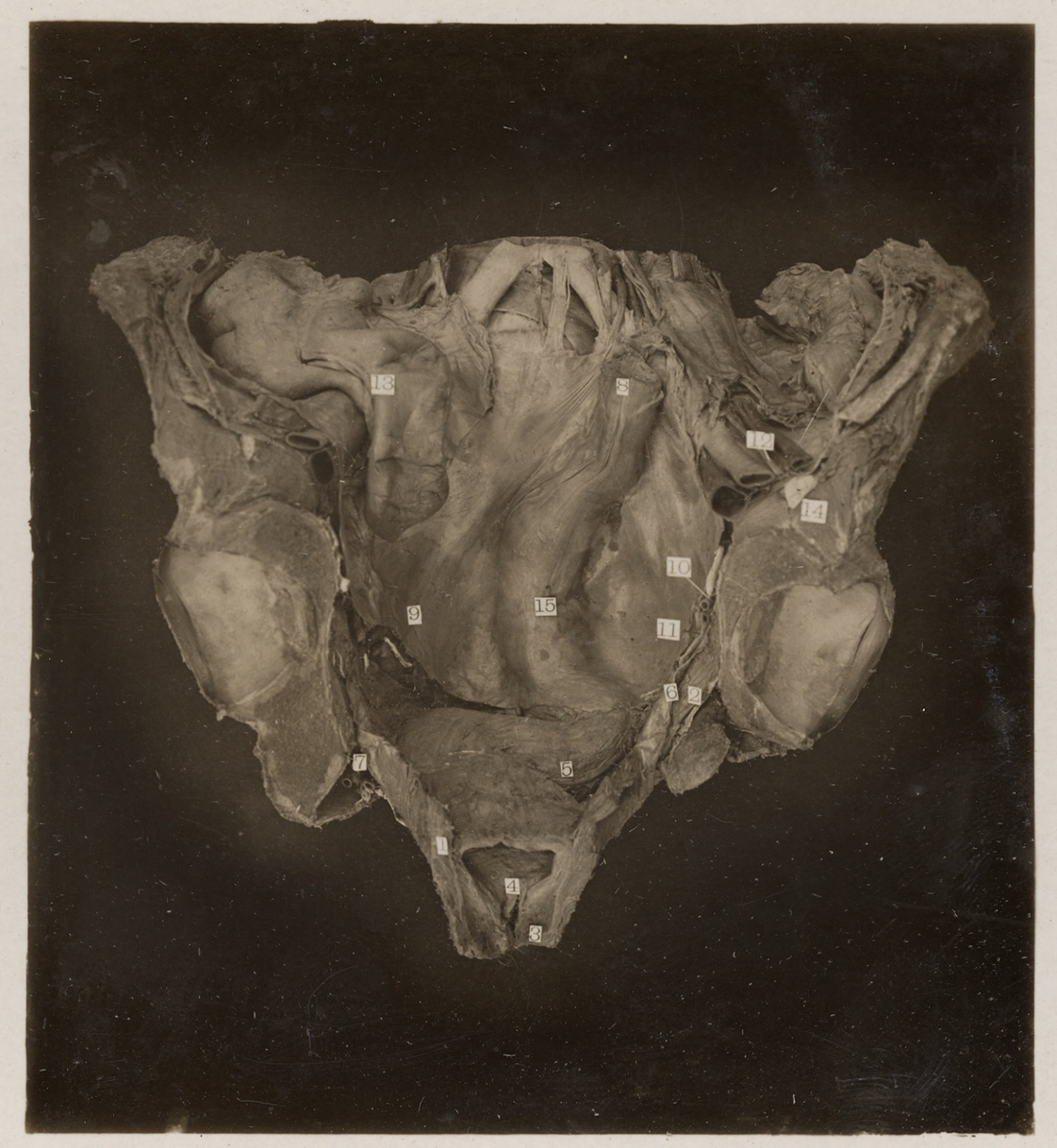
Copyright: T. C. & E. C. Jack, Edinburgh, & 34 Henrietta Street, London, W.C.