ABDOMEN.

PELVIS—No. 7.

CORONAL SECTION OF THE PELVIS, WITH THE BLADDER AND PROSTATE IN SITU.

Lining the side wall of the bony pelvis is seen the *obturator internus muscle* on the left side, with fascia on its inner and outer aspects. The fascia on its pelvic aspect gives origin to the *levator ani* muscle, and the anterior strong pillars of that muscle are seen supporting the prostate gland and passing on to blend with the wall of the anal canal. External to this muscle, on the right side of the specimen, is seen the apex of the *ischio-rectal fossa*, with the internal pudic nerve and vessels lying in its outer wall.

The *prostate* rests on the end of the rectum, and the groove between its base and the neck of the bladder was occupied by a plexus of veins and by fibrous tissue. The anal canal passes downwards and backwards from the prostate.

The vessels, nerves, and ureter lying on the side wall of the pelvis, and the vessels and nerves on the pelvic brim should be noticed.

The figures indicate—

1. Anterior portion of the levator ani.
2. Obturator internus muscle.
3. External sphincter of the anal canal.
4. Prostate, with the urethra emerging from it.
5. Seminal vesicle.
6. Fascia covering obturator internus.
7. Apex of ischio-rectal fossa, with internal pudic vessels and nerves.
8. Pelvic colon.
9. Urachus.
10. Obturator vessels and nerve.
11. Ureter.
12. External iliac vessels and genito-crural nerve.
13. Terminal part of the ileum, with the appendix vermiformis lying external and posterior to it.
14. Below the anterior crural nerve.

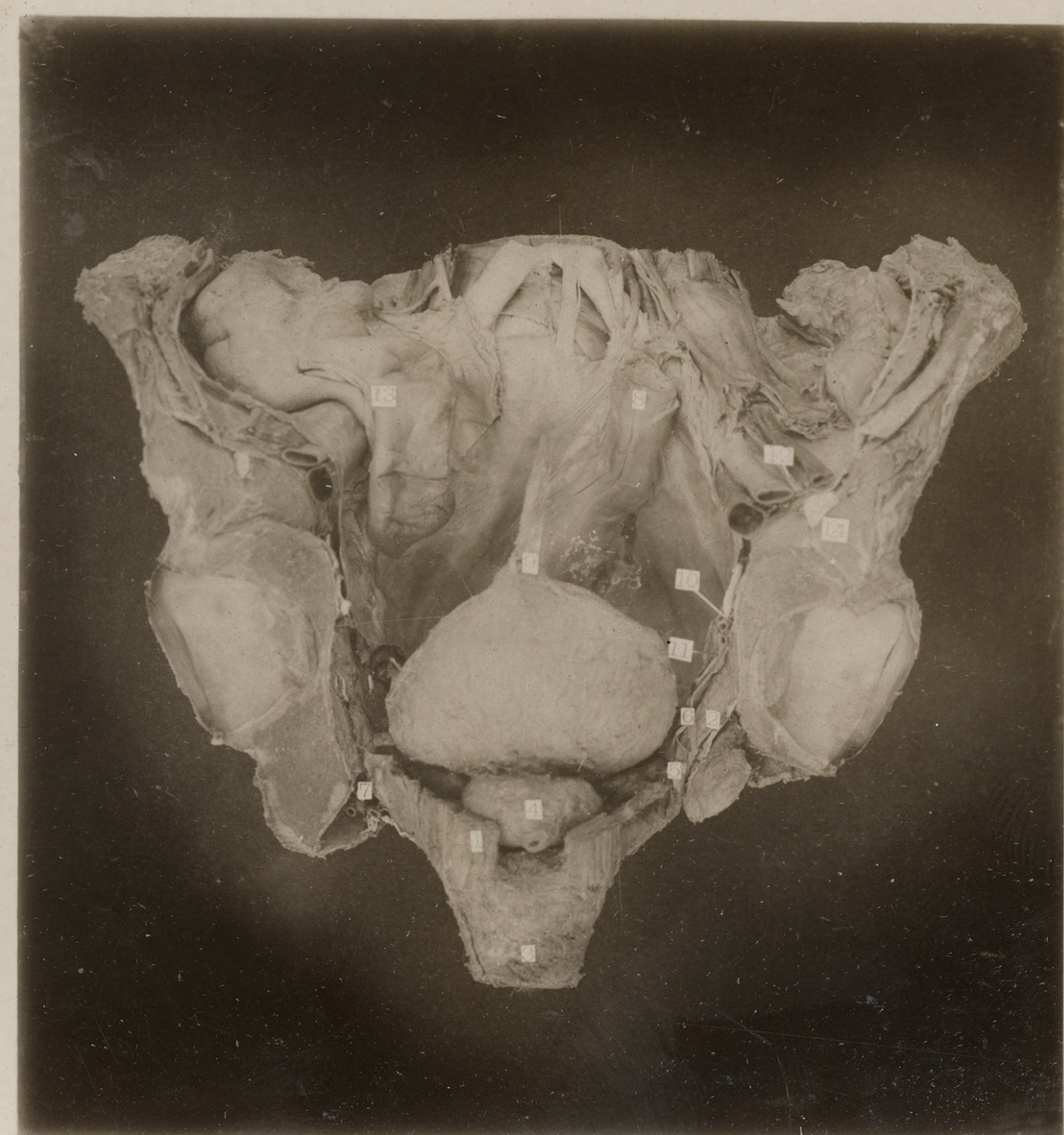

ABDOMEN—PELVIS. No. 7.

EDINBURGH STEREOSCOPIC ANATOMY

Copyright: T. C. & E. C. Jack, Edinburgh, & 34 Henrietta Street, London, W.C.