ABDOMEN.

VISCERA—No. 18.

SUPRARENAL CAPSULES, VIEWED FROM THE FRONT.

The suprarenal bodies are two small flattened ductless glands, closely related to the kidneys.

The *right,* somewhat triangular in shape, rests more upon the upper pole of the right kidney, and lies between the liver and that part of the diaphragm which covers the side of the spine.

The lower part of its anterior surface is covered by peritoneum, and the upper part is in contact with the liver externally and the inferior vena cava internally.

Near the apex is a small hilum, from which emerges a small vein which goes to join the inferior vena cava.

The *left capsule* is rather sickle-shaped, and lies more on the mesial border of its kidney. The upper part of the anterior surface is covered by the peritoneum forming the posterior wall of the lesser sac, and is related to the cardiac portion of the stomach, while the lower portion is in direct contact with the splenic vessels and the pancreas. The hilum is here situated near the lower end, and transmits a large vein, which goes to the left renal vein.

A indicates the right suprarenal and B the left, and the figures indicate—

1. The hilum.
2. Surface in contact with the inferior vena cava.
3. Peritoneal area of right capsule.
4. Surface in contact with the liver.

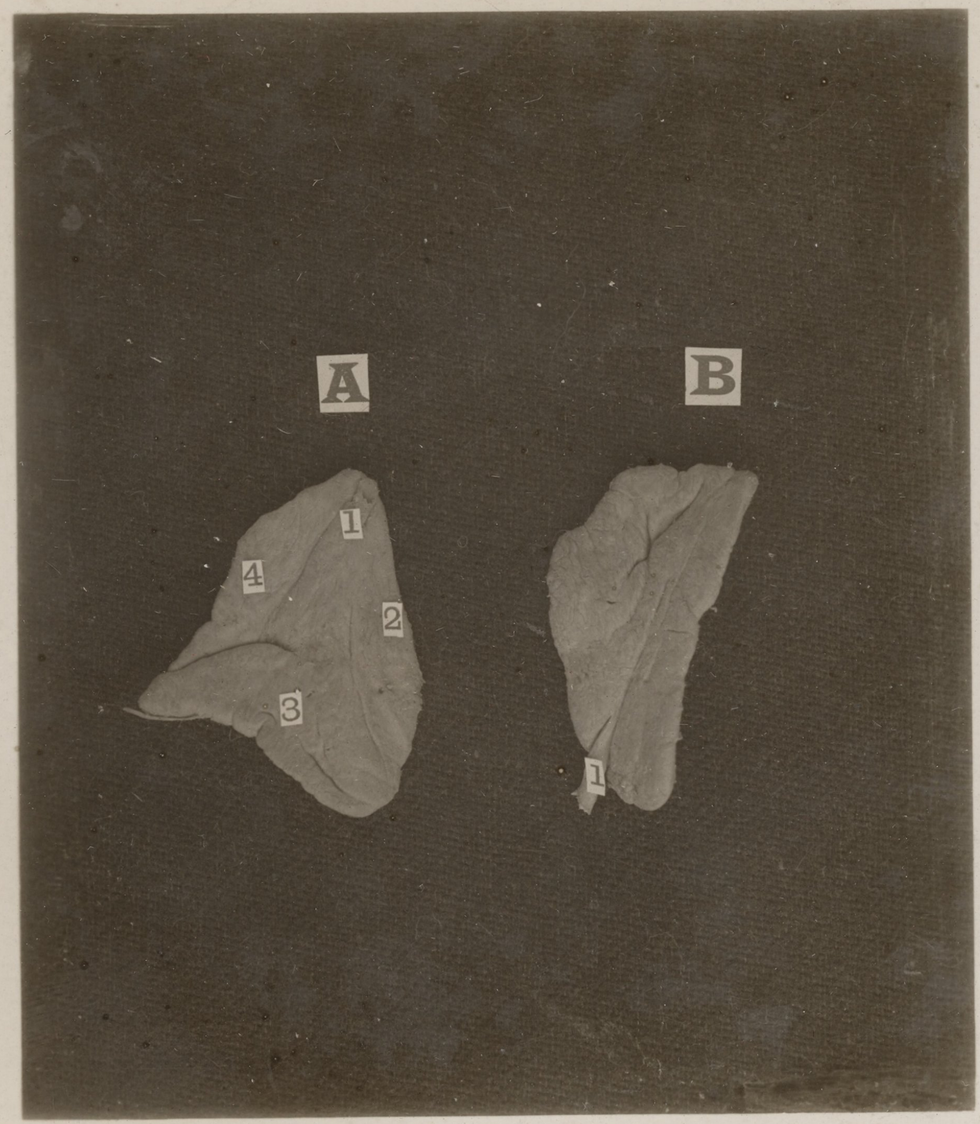

ABDOMEN—VISCERA. No. 18.

(EDINBURGH STEREOSCOPIC ANATOMY)

Copyright: T. C. & E. C. Jack, Edinburgh, & 34 Henrietta Street, London, W.C.