RELATION OF SEMICIRCULAR CANALS TO TYMPANUM OSSICLES AND MASTOID PROCESS

Due to an abnormal areation, dolichocephalic skull, and extensive cell deposits at the zygomatic root and above the tympanic attic, made it possible to demonstrate the ossicular chain and semi-circular canals without any photographic distortion. The malleus, incus and stapes are in natural position and articulation. All three semi-circular canals are open throughout their entire circumference. The short process of the incus lies across the junction of the anterior external bend of the superior and external semi-circular (horizontal) canals. The fallopian canal has been removed showing the transverse facial canal passing below and behind the long incal process, and the neck of the malleus. The narrow slit, posterior and slightly inferior to the post. semi-circular canal entering below the vestibule, at an angle of 45 degrees, is the aqueductus vestibuli.

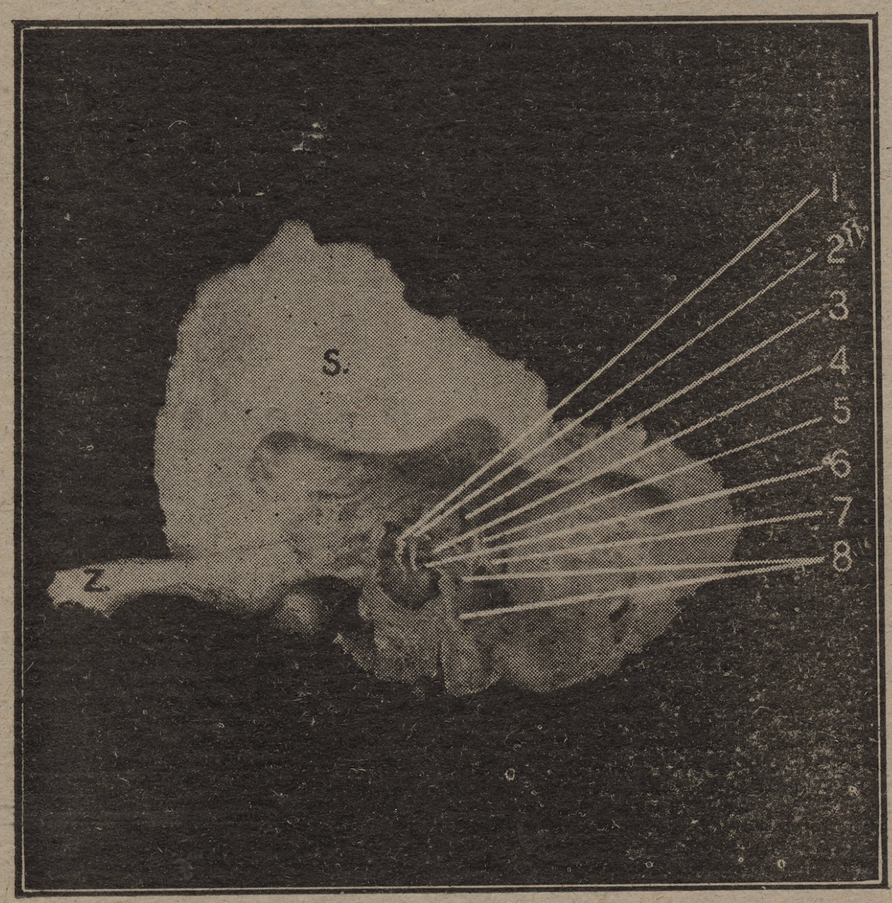

The figures indicate—

1—Malleus
2—Incus
3—Superior Semi-Cir. Canal
4—Horizontal or Ext. Semi-Cir. Canal
5—Posterior Semi-Cir. Canal
6—Stapes
7—Aqueductus Vestibuli
8—Facial Nerve

Copyrighted, 1911, by Imperial Publishing Co.

IMPERIAL PUBLISHING COMPANY - - - - - - NEW YORK