OSSICULAR RELATION TO COCHLEA

TYMPANIC VIEW. Specimen has been sawed perpendicularly through the center of the external auditory canal, meeting a lateral perpendicular sawing through eustachian tube. The posterior tympanic wall removed exposing turns of cochlea No. 5.

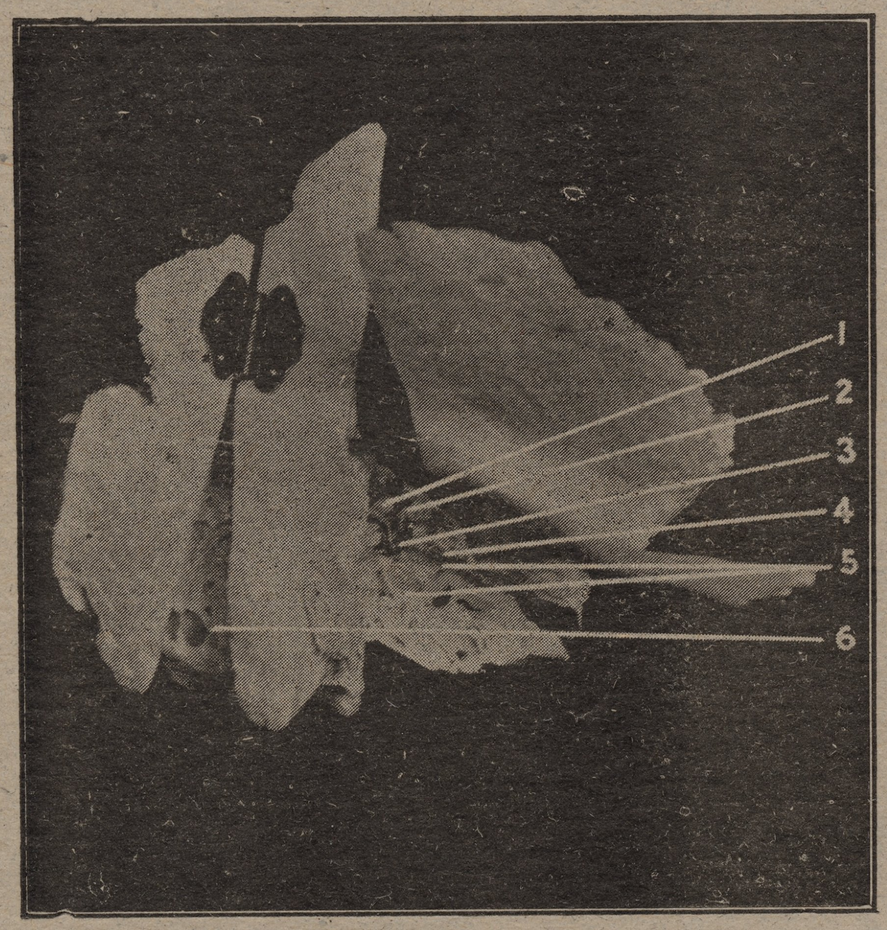

The figures indicate—

1—Incus
2—Malleus
3—Stapes
4—Tensor Tympani Muscle
5—Cochlea—Three turns
6—Mastoid Tip Cells

Copyrighted, 1911, by Imperial Publishing Co.

IMPERIAL PUBLISHING COMPANY - - - - - - NEW YORK