OSSICULAR RELATION TO ANNULAR RING

INVERSE VIEW. The entire petrous portion of the temporal bone has been removed. The natural drum membrane is preserved with the ossicles in normal relation. The position or location of the anterior surface of the mastoid antrum is well illustrated.

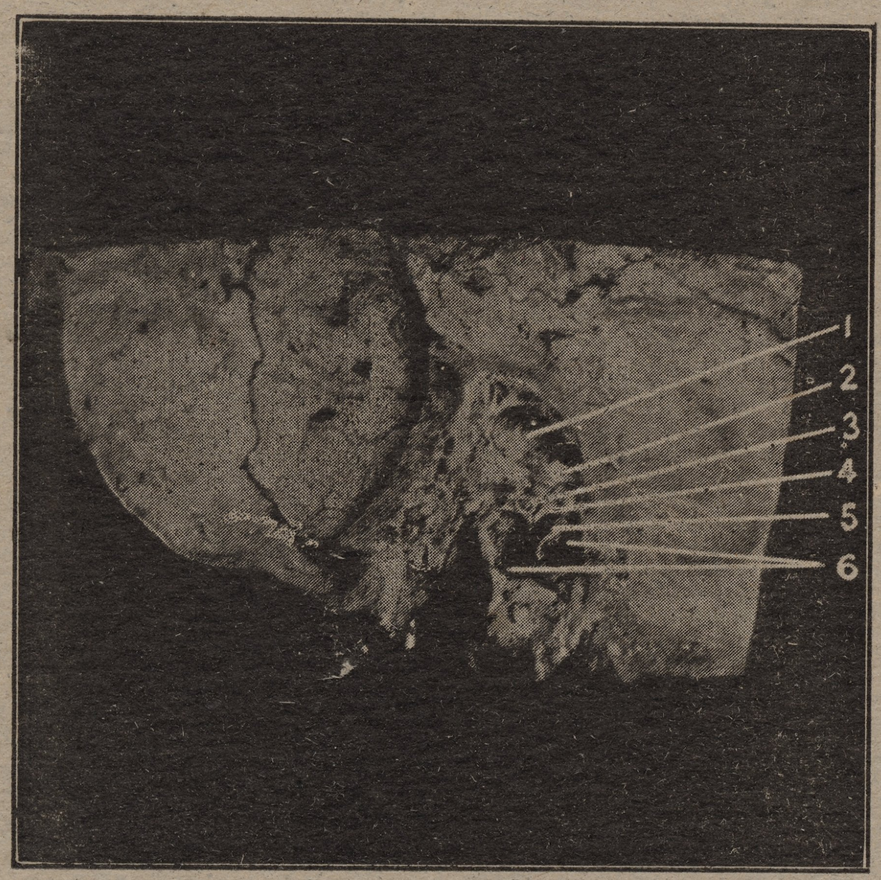

The figures indicate—

1—Antrum Anterior Surface
2—Aditus Ad. Antrum Ant. Surface
3—Stapes
4—Incus
5—Malleus
6—Drum Membrane

Copyrighted, 1911, by Imperial Publishing Co.

IMPERIAL PUBLISHING COMPANY - - - - - - NEW YORK

TION X. INO 23