OSSICULAR RELATION TO TYMPANUM

(Note—Key-plate is one-half above normal size.)

TYMPANIC VIEW. Mastoid, squamous and part of petrous portion of the temporal bone have been removed, showing malleus, incus and stapes, articulated in natural position. The processus cochliariformis No. 6, facial canal No. 8 have been opened, demonstrating the regional anatomic relation of the ossicular chain.

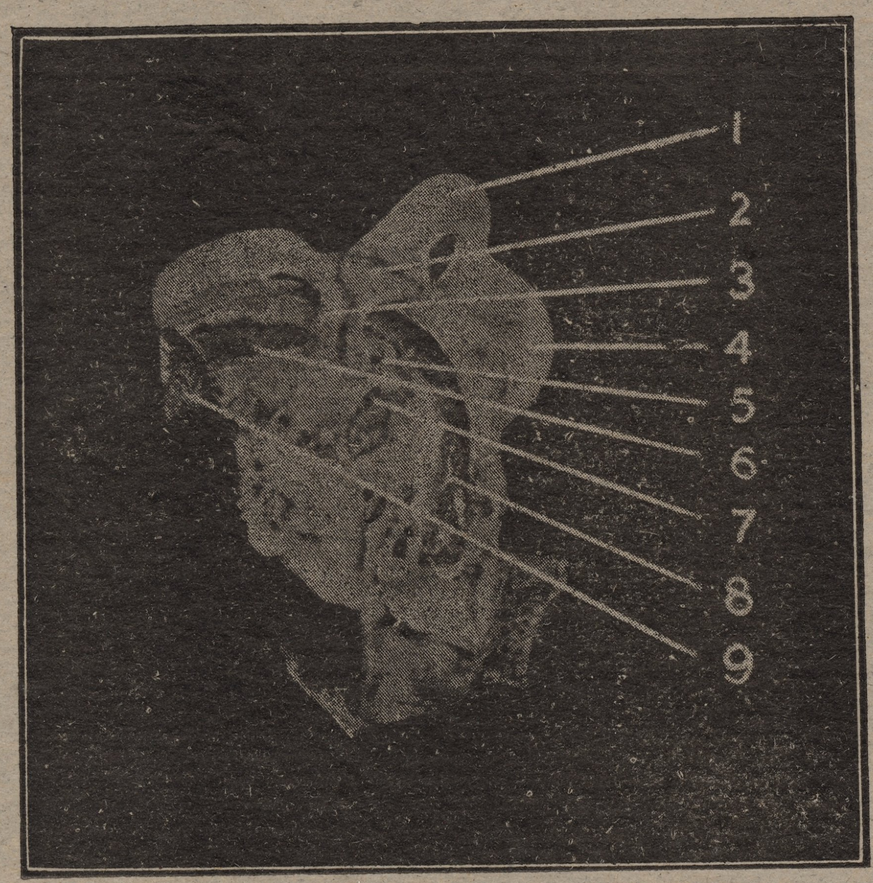

The figures indicate—

1—Superior Semi-Circular Canal
2—Incus
3—Malleus
4—Posterior Semi-Circular Canal
5—Stapes
6—Proc Cochleariformis
7—Round Window
8—Facial Canal
9—Carotid Canal

Copyrighted, 1911, by Imperial Publishing Co.

IMPERIAL PUBLISHING COMPANY - - - - - - NEW YORK

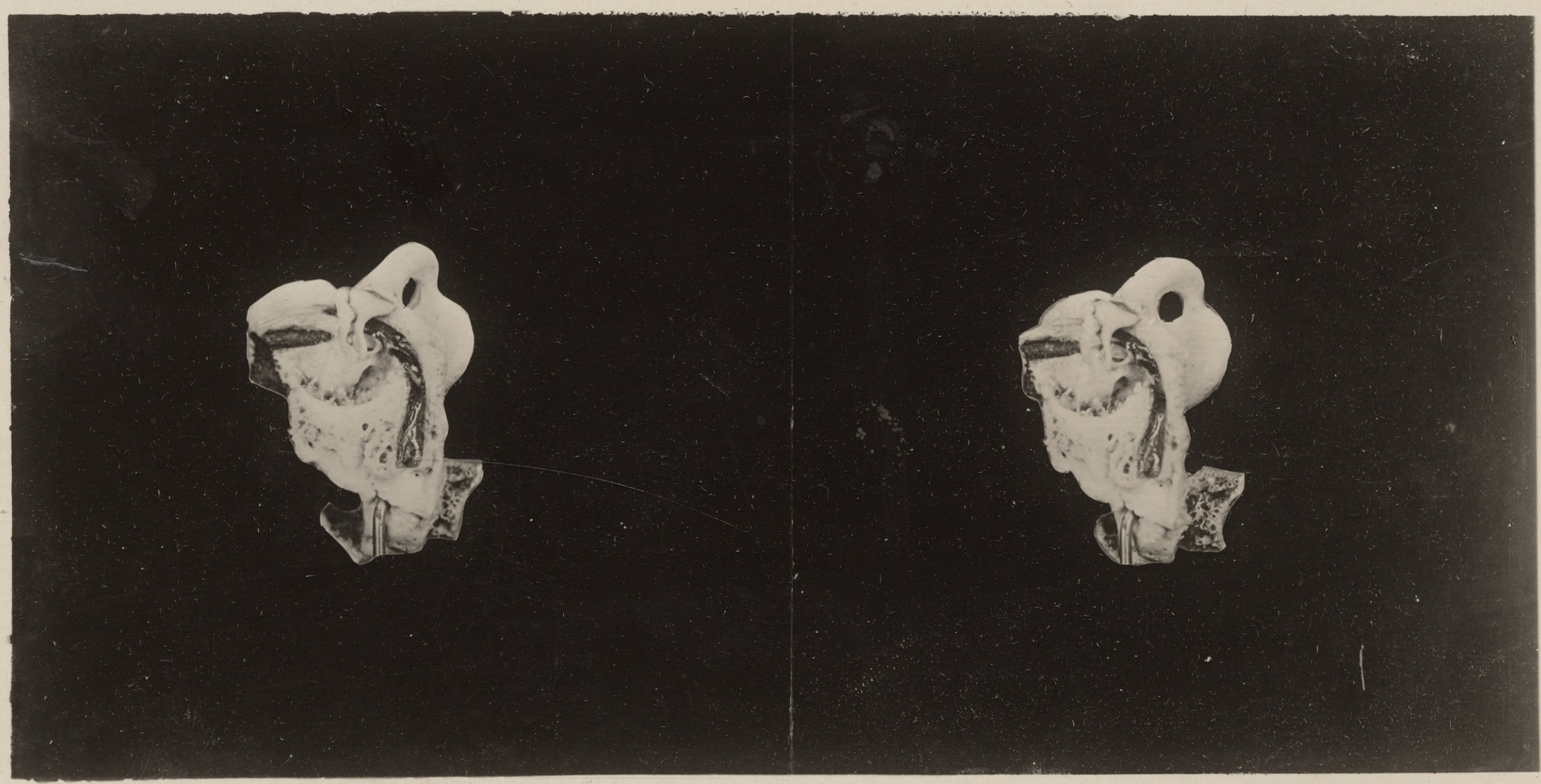

SECTION X. NO.22