VERTICAL TRANSVERSE SECTION THROUGH TYMPANUM AND MASTOID PROCESS

This specimen sawed through the same region as shown in stereogram No. 14, illustrates an abnormality, in that the lateral sinus is much more superficial and closer to the external table than is usually the case. The sinus in this relation and position is exposed by sawing the section; but well posterior.

The posterior inferior antral cells show in close proximity to the lateral sinus. The ossicles are seen resting against the posterior tympanic attic wall. The thin shell of bone above them is the typmanic tegmen. The tensor tympani muscle is exposed resting in its bony covering, forming the roof of the eustachian tube. Note the course of the descending facial canal just posterior and inferior to the ossicular chain.

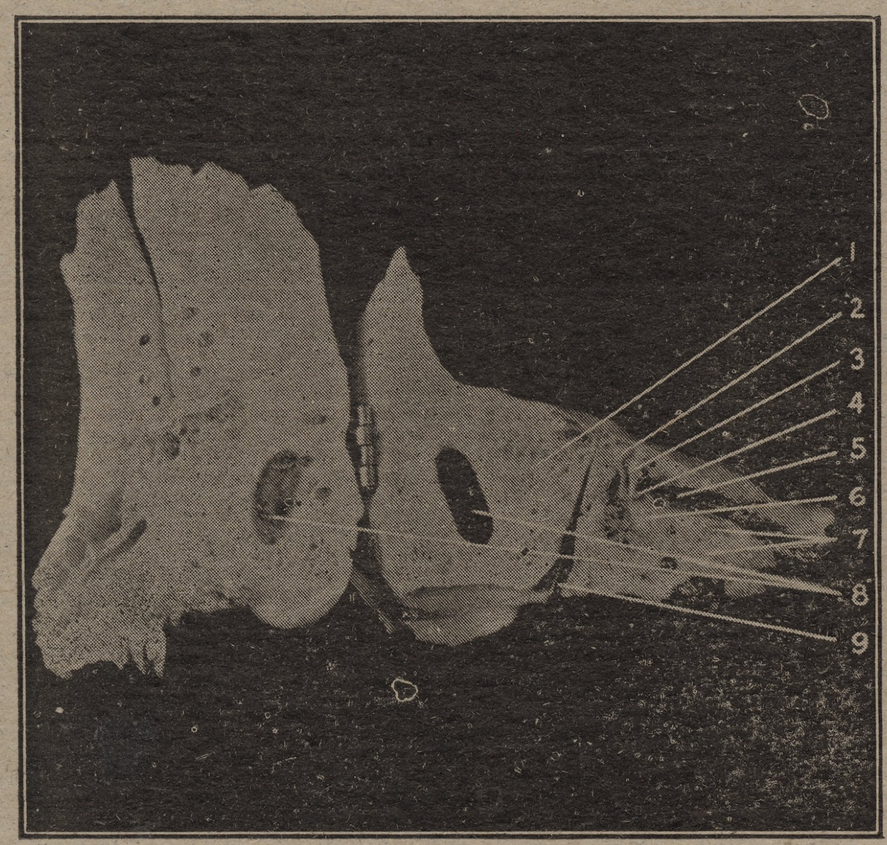

The figures indicate—

1—Post. Inferior Antral Cells
2—Incus
3—Malleus
4—Stapes
5—Tensor Tympani Muscle
6—Promontory
7—Eustachian Tube
8—Section through Lateral Sinus
9—Stylo Mastoid Foramen (Facial Nerve Exit)

Copyrighted, 1911, by Imperial Publishing Co.

IMPERIAL PUBLISHING COMPANY - - - - - - NEW YORK