FRONTAL SINUS No. 13

Made from two specimens showing lateral views of the frontal sinuses. The lower picture is a sagittal section cut near the center of the orbit, showing the anterior portion, the sinus divided into five pockets all of which have one common outlet. The sixth or posterior cell communicates with the upper meatus of the nose. The upper picture is also a sagittal section cut to the median line of the osplanum of the ethmoid bone. It shows a frontal sinus extending backward nearly to the optic nerve, which is seen in the optic foramen, and passing over the orbit; it also is divided into several pockets, and below it are seen various ethmoidal cells.

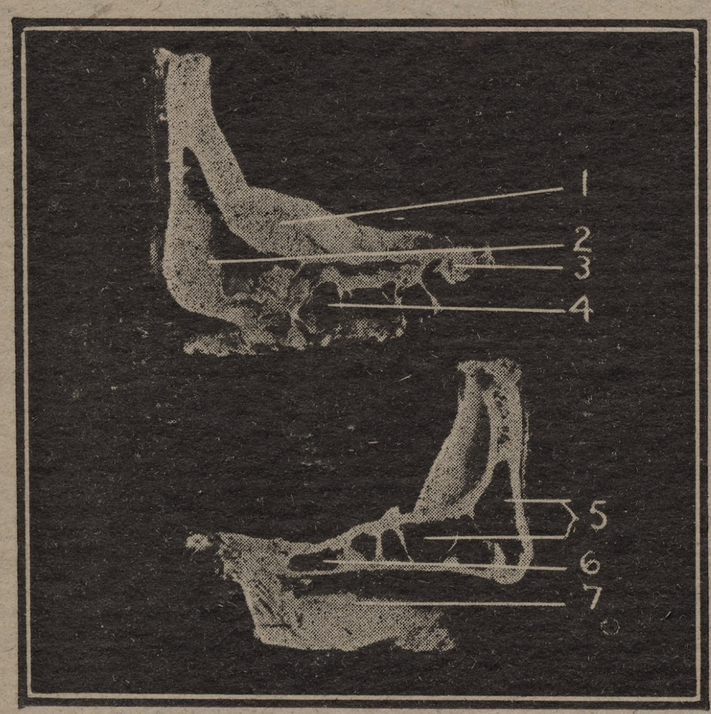

The figures indicate—

1—Crista Galli
2—Left Frontal Sinus
3—Optic Nerve in Optic Foramen or Canal
4—Ethmoidal Cells
5—Right Frontal Sinus with Septa
6—Posterior Ethmoid Cell
7—Orbit

Copyrighted by Dr. M. H. Cryer, 1909
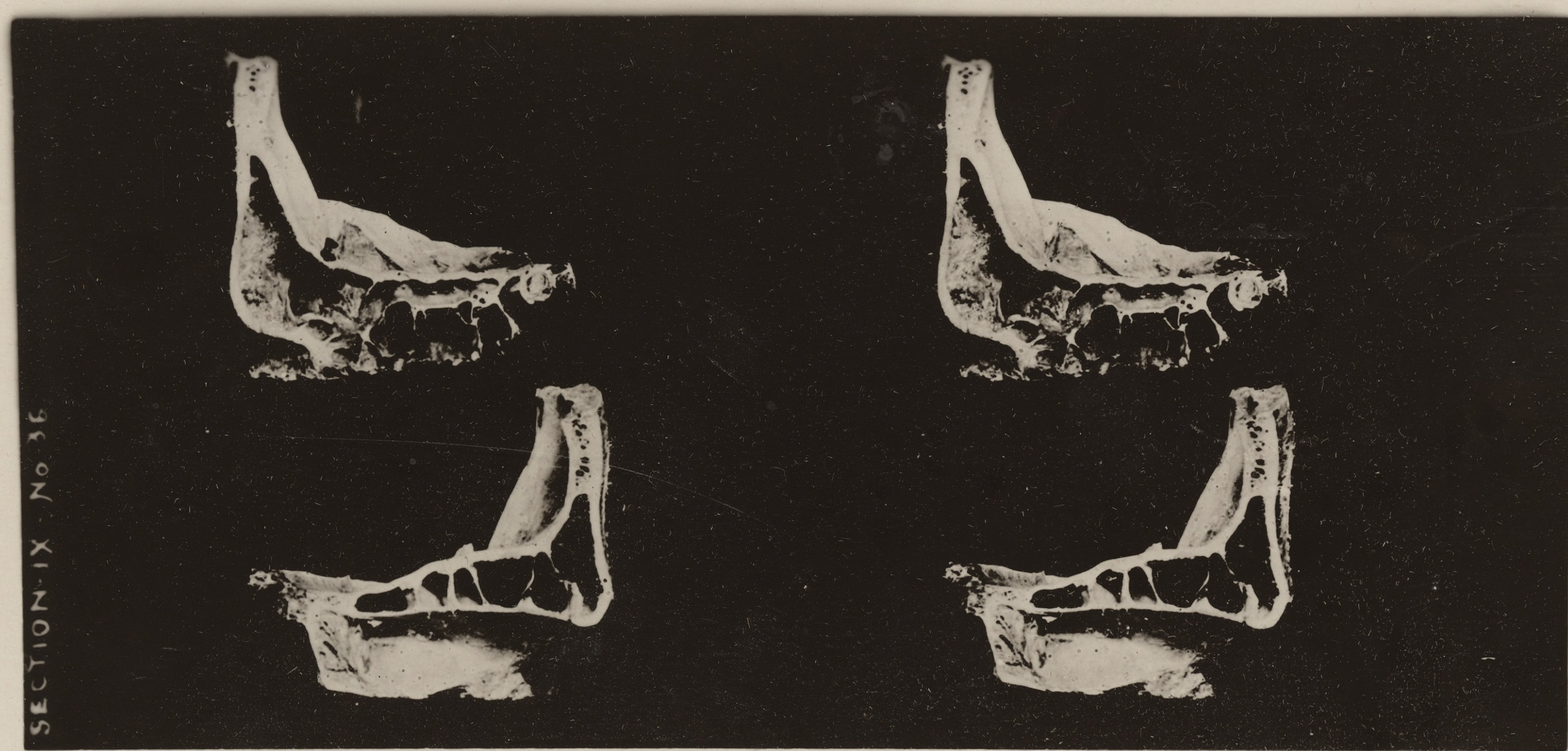
IMPERIAL PUBLISHING COMPANY - - - - - - - - NEW YORK