FRONTAL SINUS No. 2

The anterior walls in the region of the sinuses are removed, exposing a single frontal sinus,—the right,—which extends unbroken far over to the left side. This sinus extends backward partly over the orbit and has but one outlet. Originally it is possible that there were two sinuses in this case, but through pathological conditions the septum has been absorbed and the left opening into the nasal chamber has become closed.

The figures indicate—

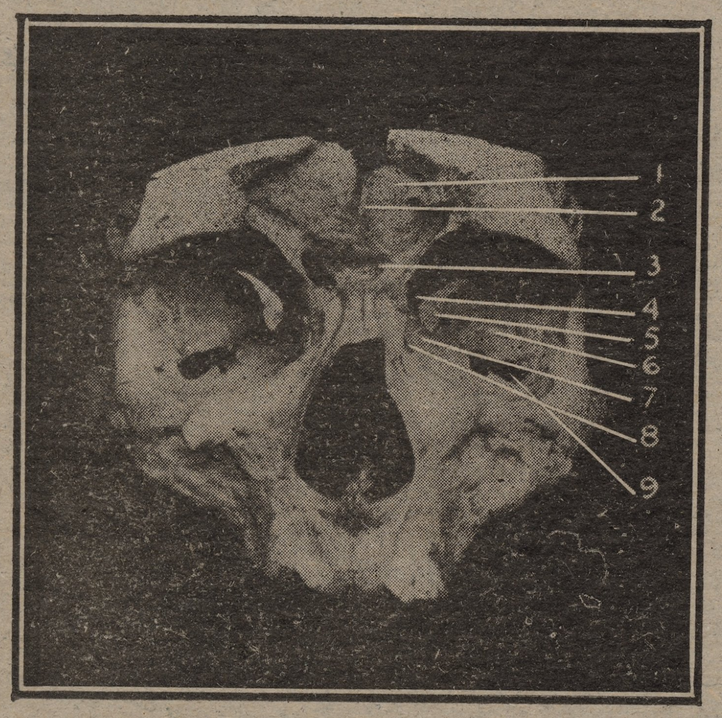

1—Frontal Sinus
2—Incomplete Septum
3—Ostium Frontale
4—Optic Foramen
5—Sphenoidal Fissure
6—Greater Wing of Sphenoid Bone
7—Lachrymal Bone
8—Nasal Duct
9—Sphenomaxillary Fissue

Copyrighted by Dr. M. H. Cryer 1909

IMPERIAL PUBLISHING COMPANY - - - - - - NEW YORK