HORIZONTAL SECTION No. 1

View from beneath of a horizontal section through the upper jaw just above the floor of the nose showing the nasal chamber and the maxillary sinuses. The center is the nasal septum and on each side are seen the edges of the superior and middle turbinate bones with the meati between them; in the roof of the inferior meatus may be seen the outlet of the lachrymal duct. In the left maxillary sinus there are two small osteophytes.

The figures indicate—

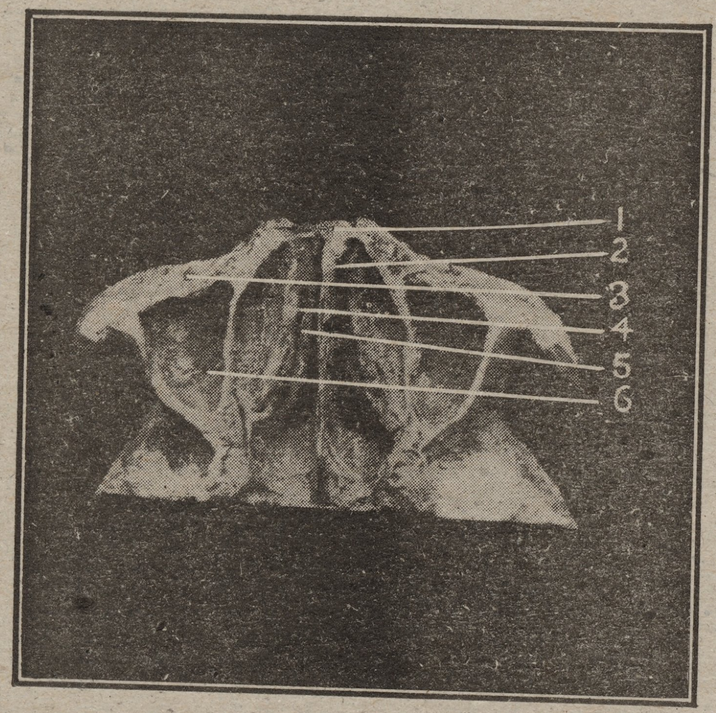

1—Anterior End of Nasal Septum
2—Nasal Septum
3—Infra-orbital Foramen
4—Inferior Turbinated Bone
5—Middle Turbinated Bone
6—Maxillary Sinus

Copyrighted by Dr. M. H. Cryer, 1909
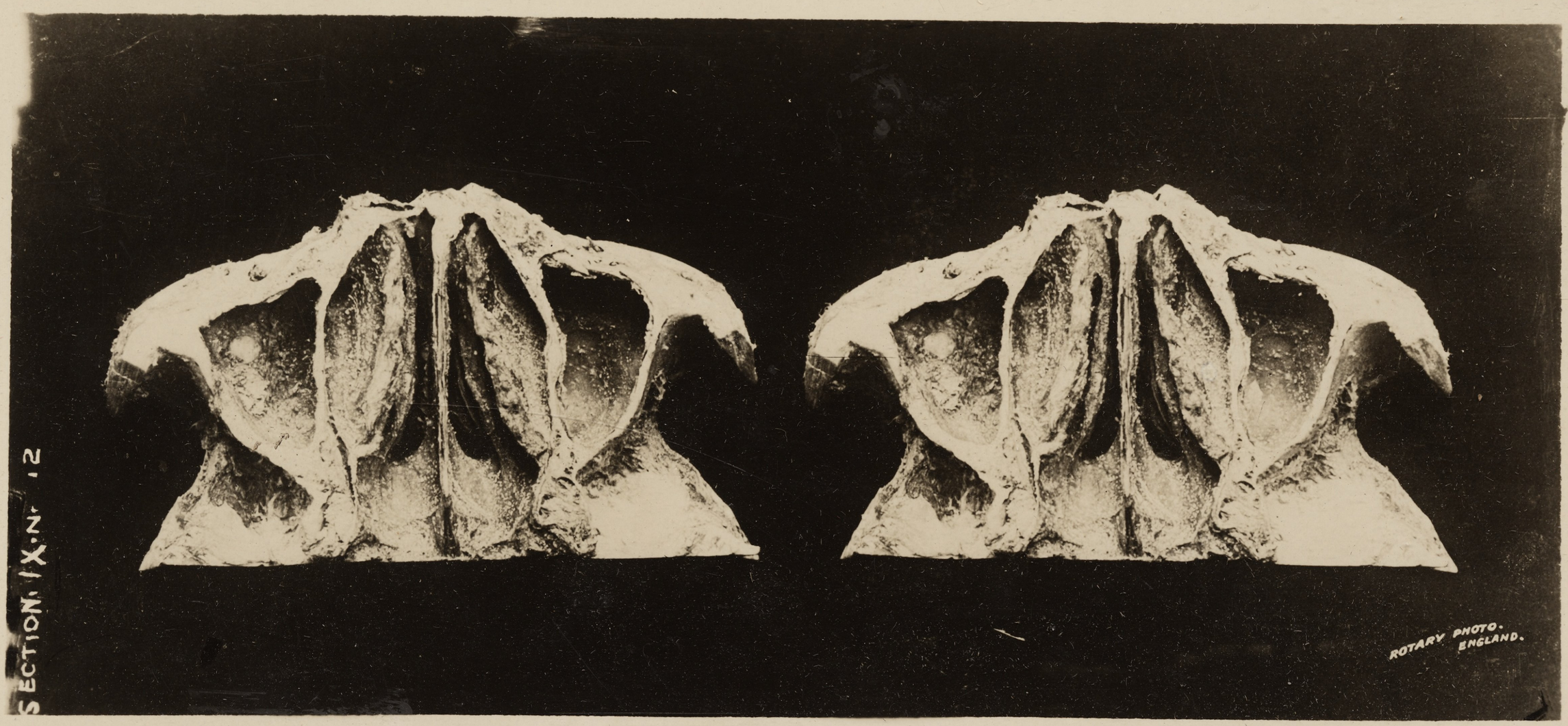
IMPERIAL PUBLISHING COMPANY - - - - - - - NEW YORK