VERTICAL TRANSVERSE BILATERAL, SECTION No. 8

A posterior view of a section cut in the region of the second premolar teeth. It shows the posterior and inferior portion of the frontal sinuses. There are two large cells within the middle turbinate bones. The infra-orbital canal of the right side is seen passing through the anterior portion of the maxillary sinus thus forming a deep pocket, the infra-orbital sinus.

The figures indicate—

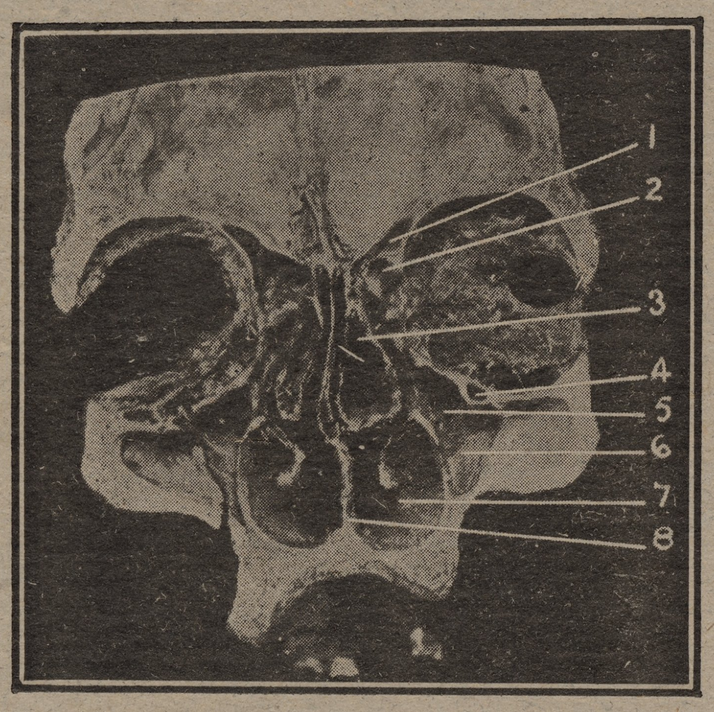

1—Frontal Sinus
2—Ethmoid Cells
3—Large Cell in Middle Turbinated Bone
4—Infra Orbital Canal
5—Infra Orbital Sinus
6—Maxillary Sinus
7—Inferior Meatus
8—Septum of Nose

Copyrighted by Dr. M. H. Cryer, 1909

IMPERIAL PUBLISHING COMPANY - - - - - - - - NEW YORK