VERTICAL TRANSVERSE BILATERAL, SECTION No. 6

Anterior view of a vertical transverse bilateral section in the region of the premolar teeth and exposing the frontal sinuses. It shows a septum deflected to the right, displacing a portion of the inferior turbinate. The frontal sinuses extend down below the middle of the orbit, and come into close juxaposition with the lachrymal duct. Between them there is an inter-frontal cell extending backward into the crista galli.

The figures indicate—

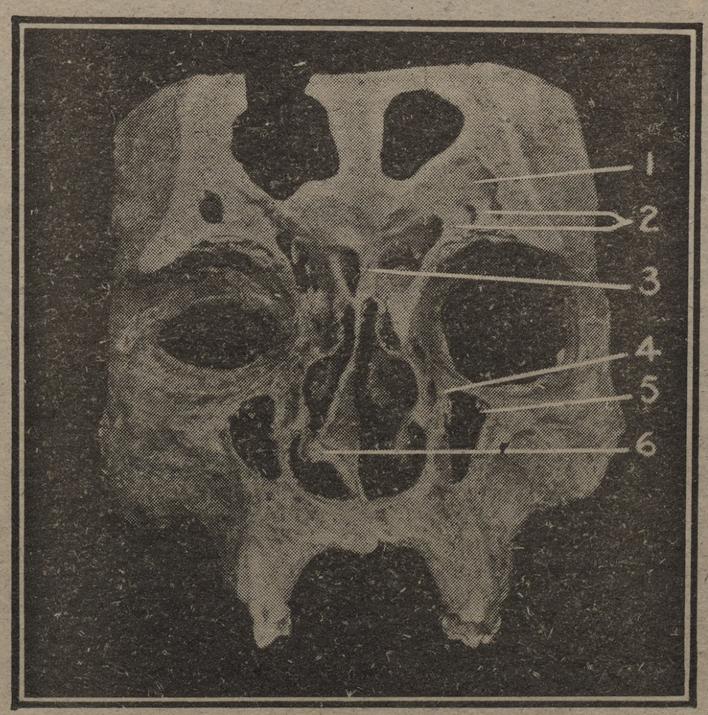

1—Frontal Sinus
2—Incomplete Septa
3—Opening Leading into Cell of The Crista Galli
4—Lachrymal Duct
5—Maxillary Sinus
6—Deflected Nasal Septum with Spur

Copyrighted by Dr. M. H. Cryer, 1909

IMPERIAL PUBLISHING COMPANY - - - - - - - - NEW YORK