

LOWER LIMB.

POPLITEAL SPACE.—No. 1.

THE SKIN AND SUPERFICIAL FASCIA HAVE BEEN REMOVED, TO SHOW THE DEEP FASCIA AND THE CUTANEOUS NERVES AND VESSELS IN THE POPLITEAL REGION OF THE LEFT LIMB.

In the roof of the popliteal space are found cutaneous branches of the small sciatic nerve, and the external and internal popliteal veins. The former vessel usually terminates by piercing the deep fascia about the middle of the space and joining the popliteal vein, which lies deeply.

Where it passes through the rigid opening in the deep fascia, it is liable to be constricted, and a varicose condition results, as shown here.

It is connected by cross-channels with the internal popliteal vein, which here is seen passing upwards behind the internal condyle of the femur.

The deep fascia is of considerable strength, and is composed largely of fibres passing across the limb, which retain the muscles and other structures in position.

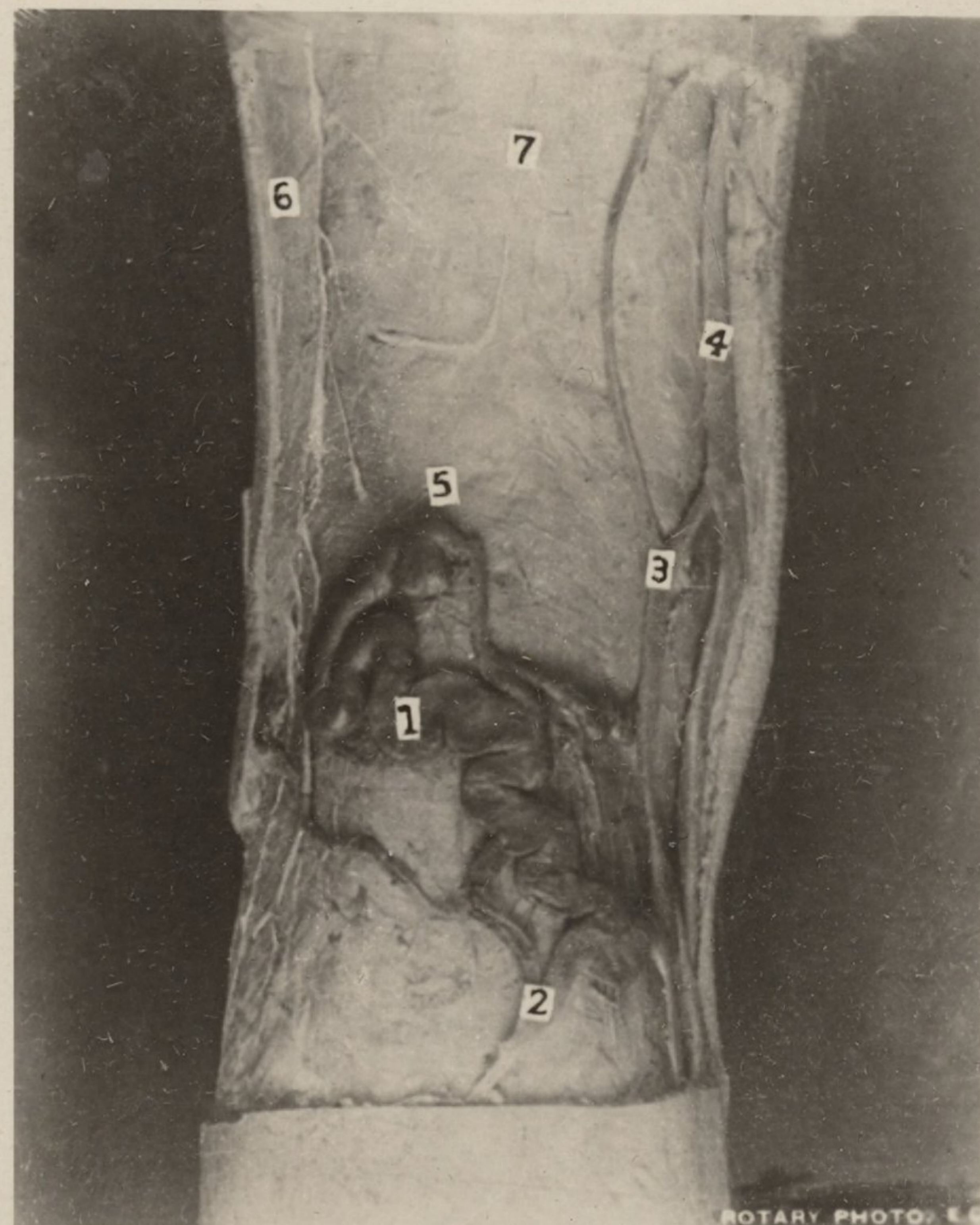
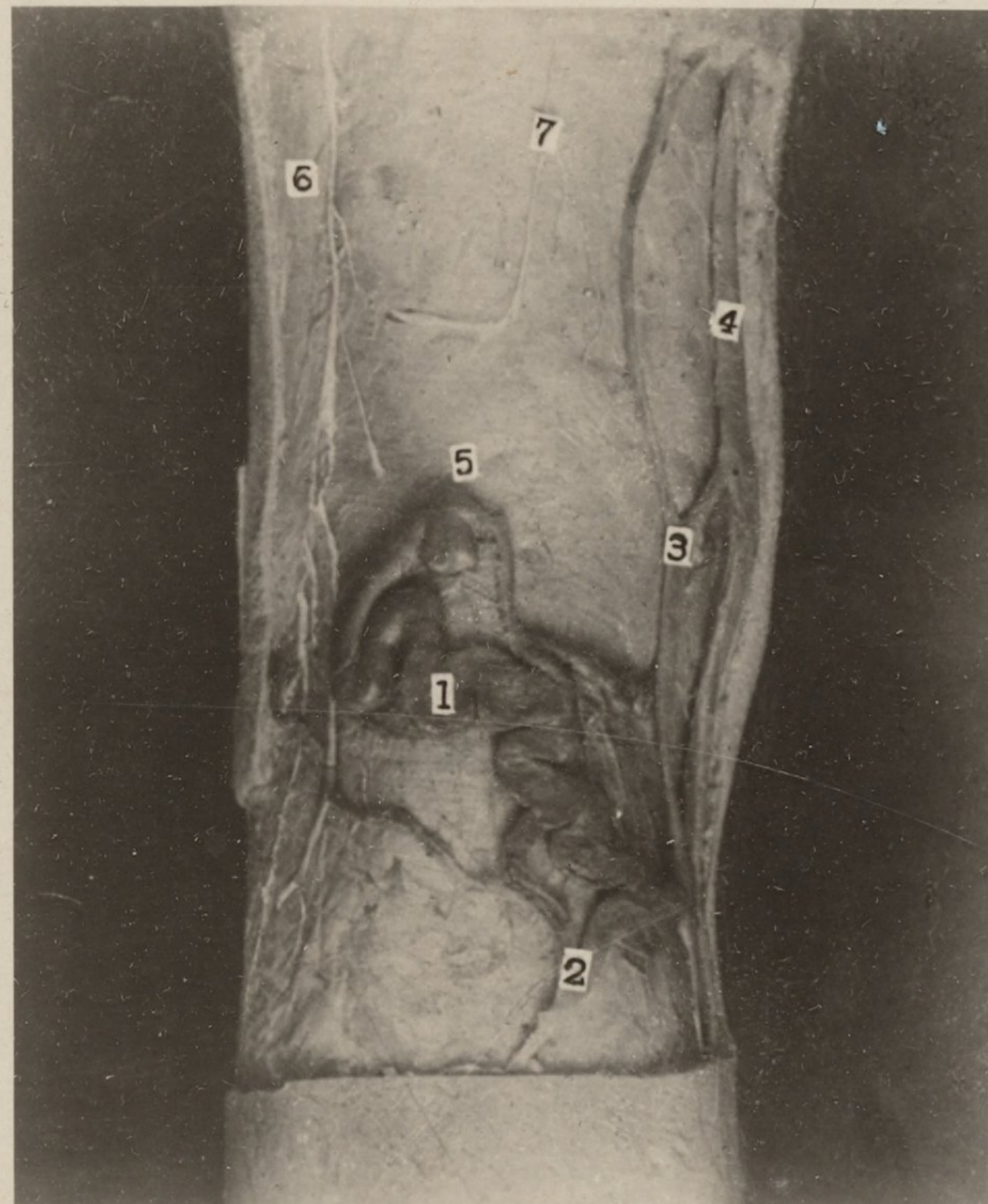
Branches of the small sciatic nerve pierce the deep fascia at intervals, and extend down to the middle of the calf.

The figures indicate—

1. External or short saphenous vein.
2. and 3. Communicating channels.
4. Internal or long saphenous vein.
5. Aperture in the deep fascia transmitting the vein.
6. and 7. Branches of small sciatic nerve.

EDINBURGH: T. C. & E. C. JACK; AND 34 HENRIETTA STREET, LONDON, W.C.

SECTION VIII
CARD NO. 13.



ROTARY PHOTO, L.C.