ABDOMEN.

PELVIS—No. 10.

THE SAME DISSECTION HAS BEEN CARRIED OUT AS IN NO. 9, AND A VIEW HAS BEEN TAKEN TO SHOW THE RECTUM AND PERITONEUM IN RELATION TO THE SACRUM AND COCCYX.

The reflection of peritoneum from the front of the rectum is seen to take place at the level of the lower end of the sacrum, and this is also the lowest limit of the pararectal fossæ.

The left fossa passes somewhat lower down than does the right, but this condition appears to be variable.

This view is intended to show the area which is available for surgical operations for the removal of the rectum by the sacral route, but the amount of the sacrum which can be taken away is strictly limited by the presence of the important sacral nerves.

The letter C indicates the first piece of the coccyx, the large 2 the posterior inferior spine of the ilium, the large 3, 4, and 5 indicate corresponding pieces of the sacrum.

The other small figures indicate:—
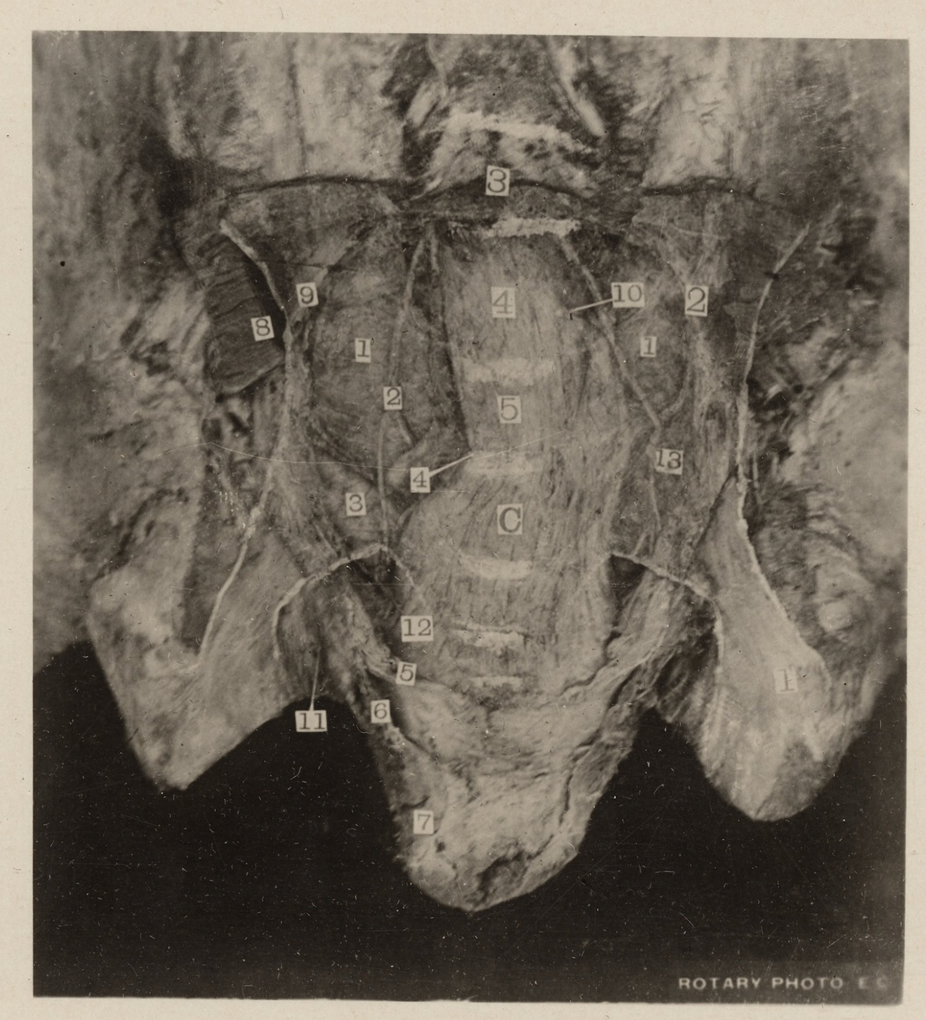
1. Reflection of peritoneum.
2. Superior hæmorrhoidal artery.
3. Seminal vesicle, left side.
4. Lower flexure of the rectum.
5. Rectal fascia.
6. Levator ani.
7. Sphincter ani externus.
8. Pyriformis.
9. Second sacral nerve.
10. Upper lateral flexure of rectum.
11. Ischio-rectal fossa.
12. Fascia investing seminal vesicle.
13. Right seminal vesicle.