PELVIS.

MALE PERINEUM—No. 5.

THE PROSTATE GLAND, FROM THE PERINEUM.

A portion of the pubic arch has been removed, with the structures related to it. The venous plexus surrounding the prostate has been removed from the left side.

The levatores ani muscles are seen passing from the back of the pubis as a sort of sling on which the prostate is supported.

The layers of fascia which invest each of the muscles on its pubic and perineal aspects meet with one another at the margin of the muscle, and are continued across to join the layer of the opposite side. The layer so formed is closely associated with the under aspect of the prostate gland, and forms the under portion of its sheath. A large plexus of veins, the prostatic plexus, lies between this sheath and the capsule of the gland, and this layer forms the deep triangular ligament.

In front, the fascia forms two strong bands which pass to the back of the pubis, and are called the pubo-prostatic ligaments.

The anterior margins of the levator ani meet and decussate in the middle line between the prostate and the anal canal, and in the interval between the prostate and the rectum there is a muscle bundle, variable in size, passing from the front of the rectum to the back of the urethra, the pre-rectalis muscle. It is seen here, divided.

The obturator internus muscle has been divided vertically on each side. On its pelvic aspect this muscle is invested by a strong sheet of fascia, the parietal pelvic fascia.

This fascia blends with the fascia covering the outer surface of the levator ani muscle along a line which forms the white line of the pelvic fascia, and corresponds to the apex of the ischio-rectal fossa.

Lower down, the internal pudic vessels and nerve run in a sheath formed by this fascia in the outer wall of the ischio-rectal fossa, called Alcock's canal.

The lumen of the urethra is, of course, seen to be merely a stellate fissure on the cut surface. The walls are of considerable thickness, and the portion seen is the termination of the membranous urethra, passing into the interior of the prostate gland.

The figures indicate:—
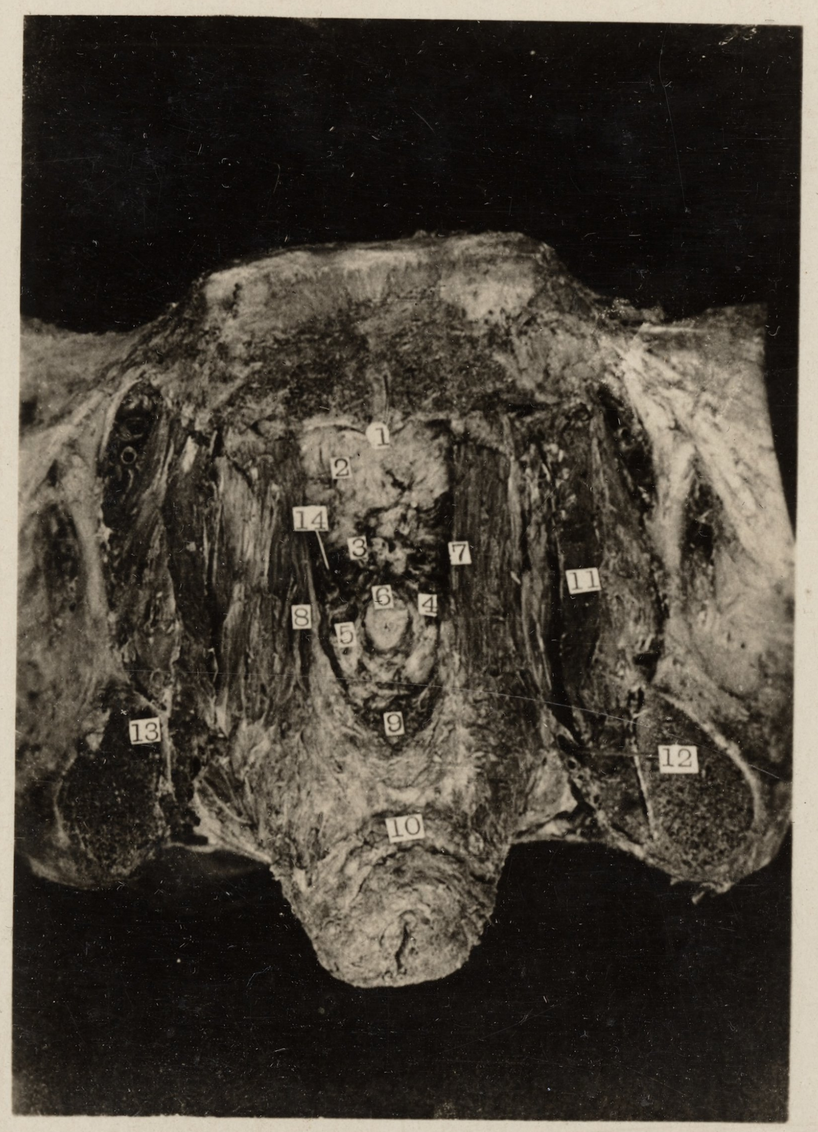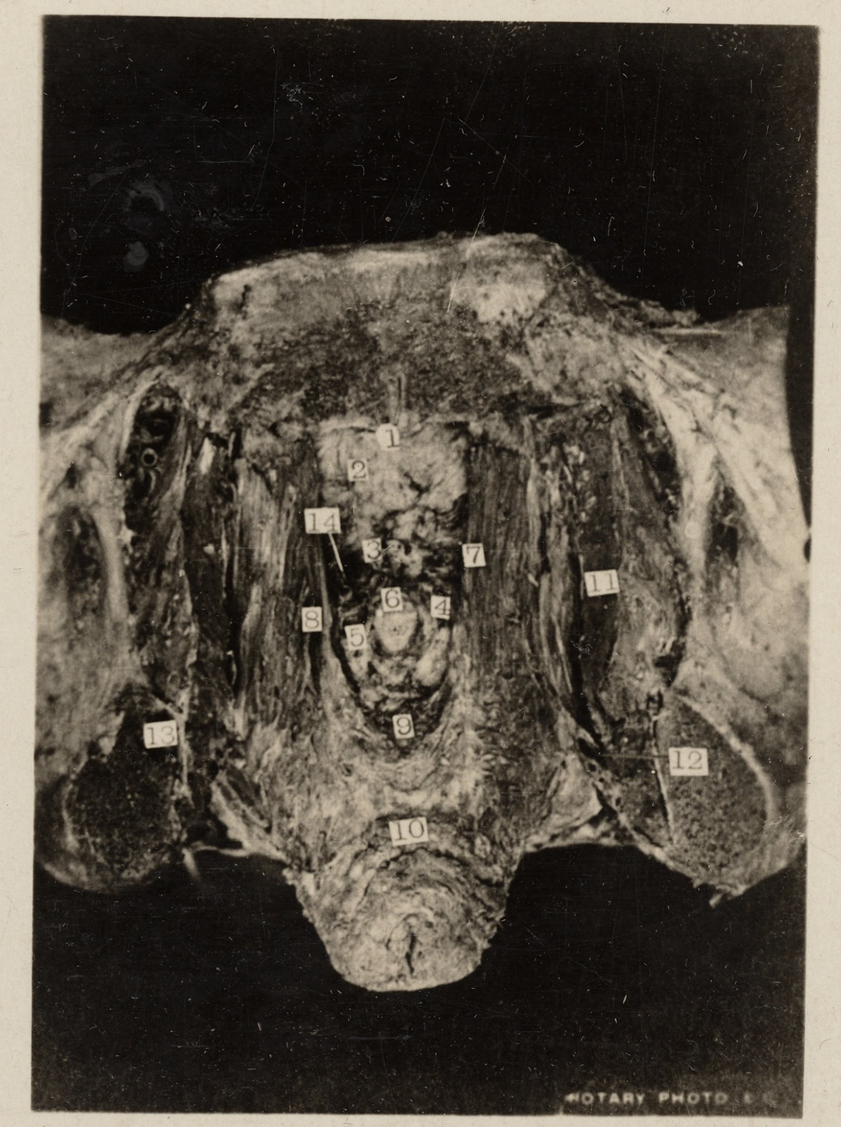
1. Symphisis pubis.
2. Bladder.
3. Pubo-prostatic bands (divided)
4. Prostate.
5. Capsule of prostate.
6. Urethra.
7. Levator ani.
8. Fascia (anal) of levator ani.
9. Prerectalis muscle (divided).
10. External sphincter
11. Obturator internus muscle.
12. Alcock's canal.
13. Ramus of ischium (divided).
14. Prostatic plexus of veins.