ABDOMEN.

VISCERA—No. 17.

INNER BORDER OF THE RIGHT KIDNEY, VIEWED FROM THE INNER SIDE.

The *hilum* on the inner border of the kidney is bounded by two convex margins, irregular in outline and variable as regards their relative size.

In the hilum are lodged the branches of the renal vein and artery and the ureter, in that order from before backwards.

The *hilum* leads into a slit, called the *renal sinus*, in which lies the *pelvis* of the kidney.

As not infrequently happens, in this specimen there are several renal arteries, each accompanied by a vein.

An inferior capsular vessel is seen going to the suprarenal capsule, which lies mainly on the inner border of the kidney, a short distance above the hilum.

The figures indicate—

1. Suprarenal capsule.
2. Principal renal vein.
3. A renal artery, branching at the hilum.
4. Ureter, accompanied by an artery.
5. Anterior lip of the hilum.
6. Posterior lip of the hilum.
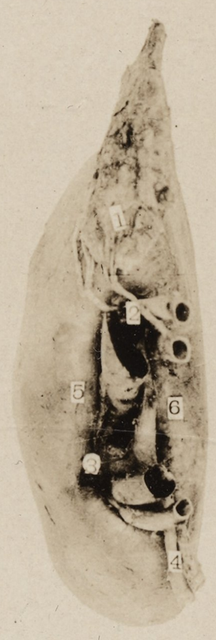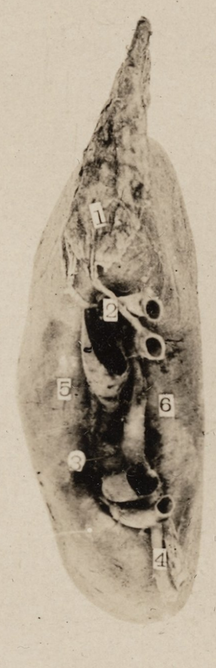
SECTION VI CARD NO. 17