ABDOMEN.

VISCERA—No. 8.

DUODENUM, PANCREAS, AND BILE-DUCTS.

The greater part of the head of the pancreas has been removed, so as to show the terminal part of the common bile-duct.

The second and third parts of the duodenum are seen forming a loop, in which the head of the pancreas lay, and terminating at the duodeno-jejunal flexure.

The superior mesenteric vessels have been cut across as they emerged from the pancreas, and the superior pancreatico-duodenal and right gastro-epiploic arteries are seen to their right side. The *common bile-duct* is seen posteriorly, running along the side of the duodenum and terminating by piercing its walls at the end of the second part. This duct was joined by the principal pancreatic duct, shortly before entering the wall of the duodenum; but, as is occasionally found, there is an accessory duct from the pancreas in this case, which terminates in the duodenum a little above this point. The inferior vena cava is seen lying in a still more posterior plane.

The figures indicate—
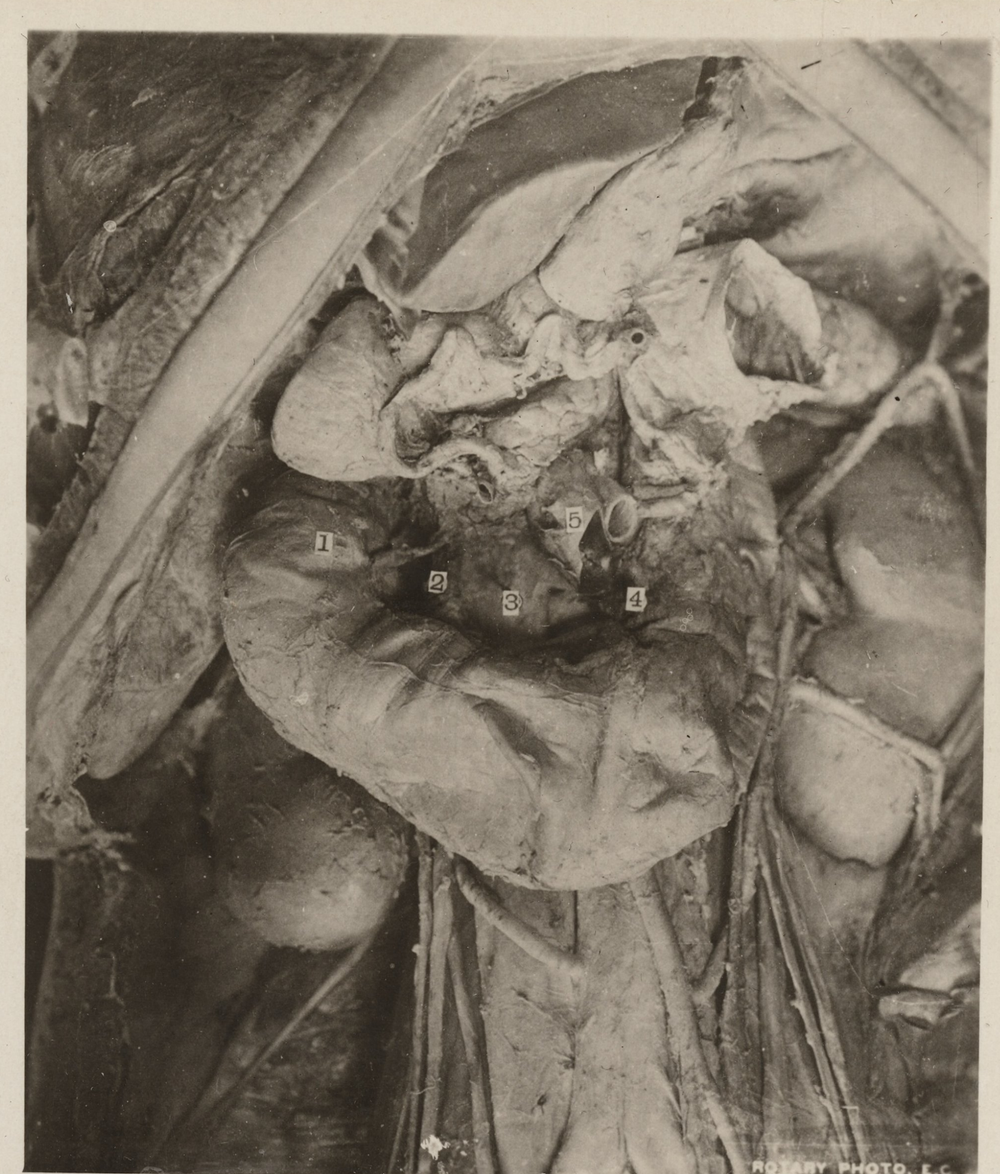
1. Second part of the duodenum.
2. Common bile-duct.
3. Inferior vena cava.
4. Ascending part of duodenum.
5. Superior mesenteric vein, with the artery on its left side.