ABDOMEN.

VISCERA—No. 1.

STOMACH, LIVER, AND DUODENUM

(From a young subject.)

The STOMACH is seen to lie nearly horizontally, in the left hypochondriac and epigastric regions. The pyloric orifice lies near the mesial plane of the body, and its position is indicated by an annular constriction. From this point, the FIRST PART of the DUODENUM passes backwards, and comes into contact with the neck of the gall-bladder; the SECOND PART passes downwards, between the head of the pancreas and the hepatic flexure of the colon, and, in this specimen, in front of the right kidney; and the THIRD PART passes to the left and then upwards, in front of the body of the third lumbar vertebra.

The positions of the hepatic and splenic flexures of the colon should be noticed, lying far back, and in contact with their areas on the liver and spleen respectively.

The figures indicate—

1. Body of the stomach.
2. Antrum pylori.
3. Pylorus.
4. First part of duodenum.
5. Ligamentum teres of the liver.
6. Gall bladder.
7. Hepatic flexure of the colon.
8. Right kidney.
9. Spleen.
10. Pancreas and superior mesenteric vessels, cut across.
11. Splenic flexure of colon.
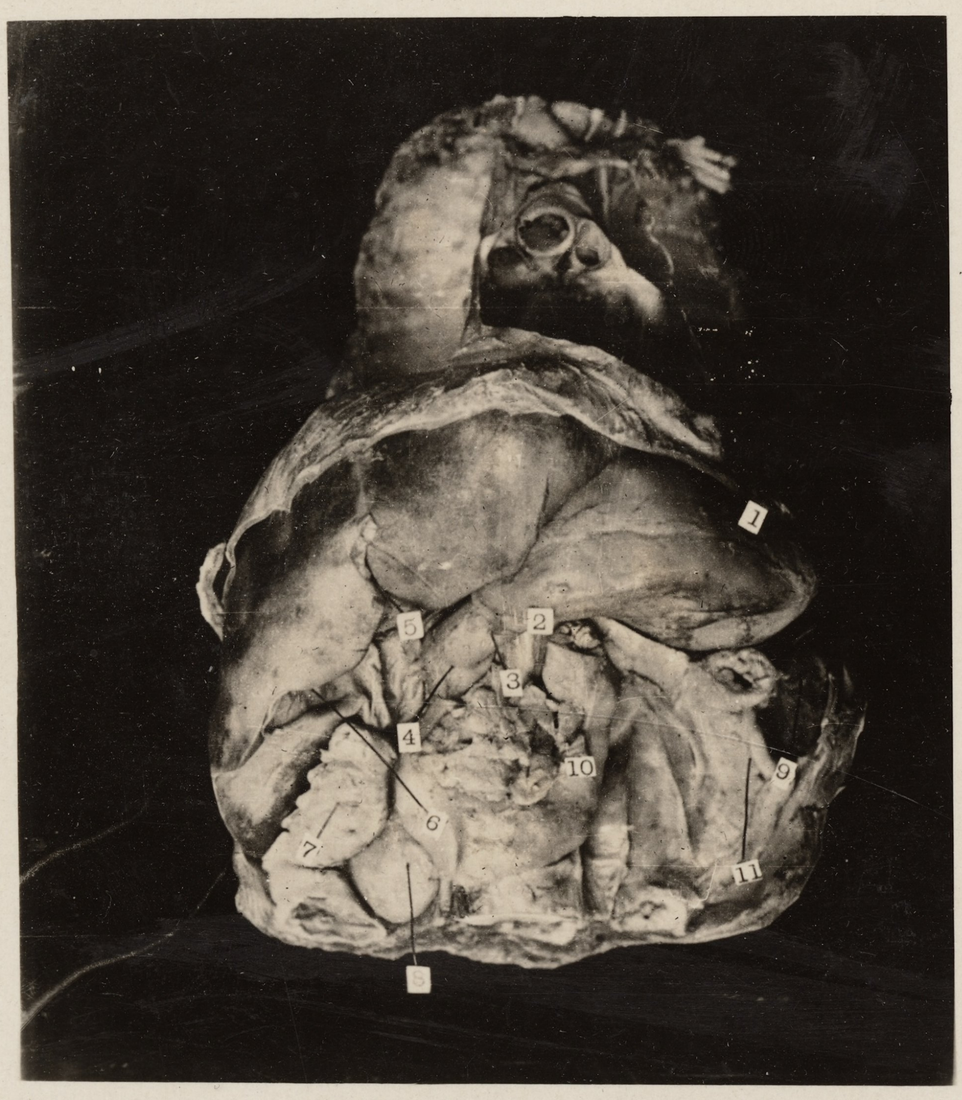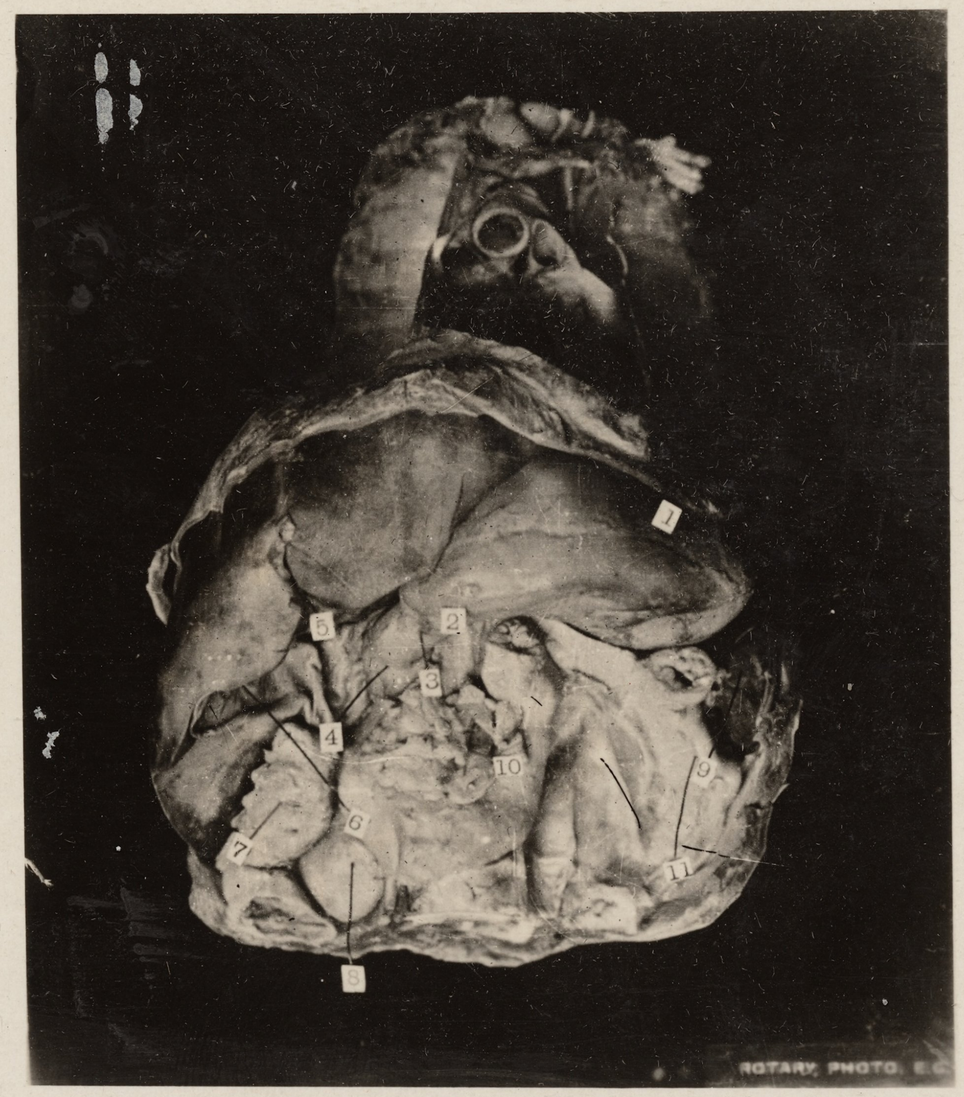
SECTION VI CARD NO. 1