LUMBAR REGION—No. 2.

ON THE RIGHT SIDE, MUSCLES AND APONEUROSIS HAVE BEEN REMOVED TO SHOW THE ERECTOR SPINÆ, WHILE ON THE LEFT, THE GREATER PART OF THE ERECTOR SPINÆ HAS BEEN REMOVED TO SHOW THE MULTIFIDUS SPINÆ.

The erector spinæ muscle and prolongations from it fill up the hollow on either side of the vertebral column. The muscle itself consists of a flattened tendinous portion which lies superficially in the lumbar and sacral regions, and of a mass of fleshy tissue which lies on its anterior surface. From the origin of the muscle bands pass in different directions to gain insertion into ribs and vertebræ. The three principal columns into which the muscle divides are shown here. They are the ilio-costalis on the outer side, the longissimus dorsi in the centre, and the spinalis dorsi close to the vertebral spines. Cutaneous nerves emerge between the first two.

The multifidus spinæ in this region is a thick fleshy mass, covered by the erector spinæ, the bundles of which it is composed passing upwards and inwards to be inserted into the vertebral spines.

In front of these structures lies the quadratus lumborum, its outer margin projecting beyond that of the vertebral muscles.

The lumbar aponeurosis, the middle lamella of which covers the quadratus lumborum, and which gives origin to the internal oblique and transversalis abdominis muscles, has been removed, so that the descending colon is visible, with some nerves.

The figures indicate—

1. Posterior superior iliac spine.
2. Sacral cornu.
3. Last rib.
4. Transverse process of first lumbar vertebra.
5. Spine of second lumbar vertebra.

Muscles. 6. Quadratus lumborum.
7. Ilio-costalis.
8. Musculus accessorius.
9. Longissimus dorsi.
10. Spinalis dorsi.
11. Multifidus spinæ.
12. Levator costæ.
13. External intercostal.
14. Lumbar aponeurosis, middle lamella.
15. Extraperitoneal fat, and ilio-inguineal and ilio-hypogastric nerves.

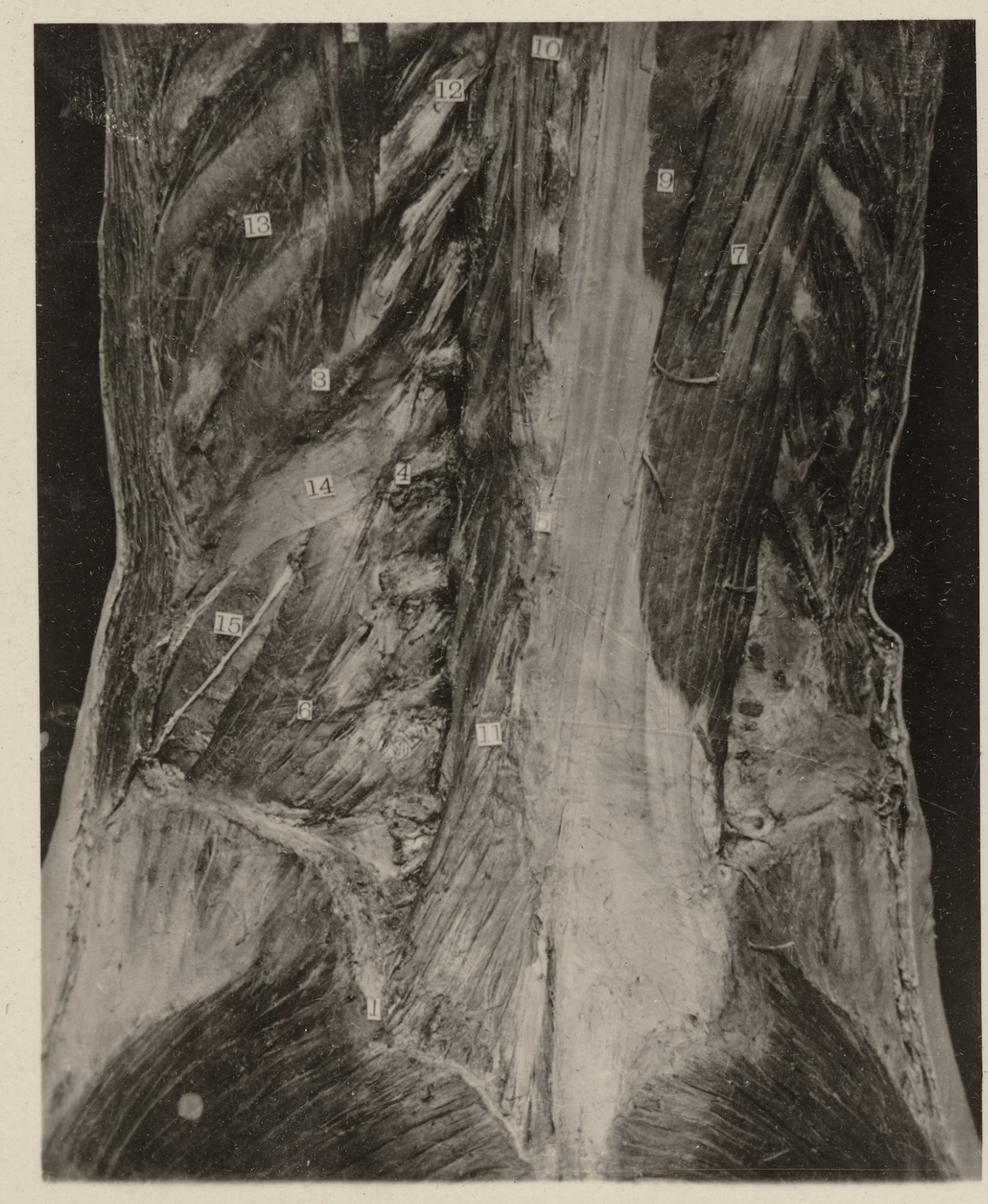

SECTION V CARD NO. 26