LUMBAR REGION.—No. 1.

THE SKIN AND LAYERS OF FASCIA HAVE BEEN REMOVED, LEAVING THE CUTANEOUS NERVES, TO SHOW THE MUSCLES.

The cutaneous nerves of the lower part of the back are derived from the posterior primary divisions of spinal nerves.

From the lower six dorsal nerves branches are given to the skin through the external branches of these nerves, and branches, lower down, are given off by the upper three lumbar, and from two or three sacral nerves.

The lumbar nerves become cutaneous by piercing the lumbar aponeurosis near the outer margin of the erector spinæ, while the sacral twigs pierce the gluteus maximus.

The **latissimus dorsi** arises from the spines and supra-spinous ligaments of the lower six dorsal vertebræ, from the posterior lamella of the lumbar aponeurosis, by which it is attached to the lumbar spines, to the sacrum and iliac crest, and it also gains a separate origin from the crest of the ilium in front of the attachment of the lumbar aponeurosis. It may also gain a few fibres from the dorsal surface of the lower angle of the scapula. It is also attached to the lower three or four ribs.

The **triangle of Petit** is a small triangular intermuscular interval, above the crest of the ilium between the latissimus dorsi and external oblique muscles. It is a weak point in the abdominal wall, and may be the site of a lumbar hernia.

The **bony landmarks** which attract attention are—(1) the crest of the ilium, (2) the posterior superior iliac spines, which are on a level with the second sacral spine, (3) the sacral cornua, between which is a depression corresponding to the inferior opening of the sacral canal.

The prominence of the erector spinæ muscle is of importance, and especially the furrow at its outer margin, where the three layers of the lumbar aponeurosis unite with one another.

This furrow is a useful landmark in operations on the kidneys from the back.

The figures indicate—

1. Trapezius.
2. Latissimus dorsi.
3. Triangle of auscultation.
4. Rhomboideus major.
5. External oblique of abdomen.
6. Lumbar aponeurosis.
7. Triangle of Petit.
8. Gluteus medius.
9. Gluteus maximus.
10. Posterior superior iliac spine.
11. Sacral cornua.
12. Internal cutaneous branch.
13. External cutaneous branch.
14. Lumbar cutaneous branch.

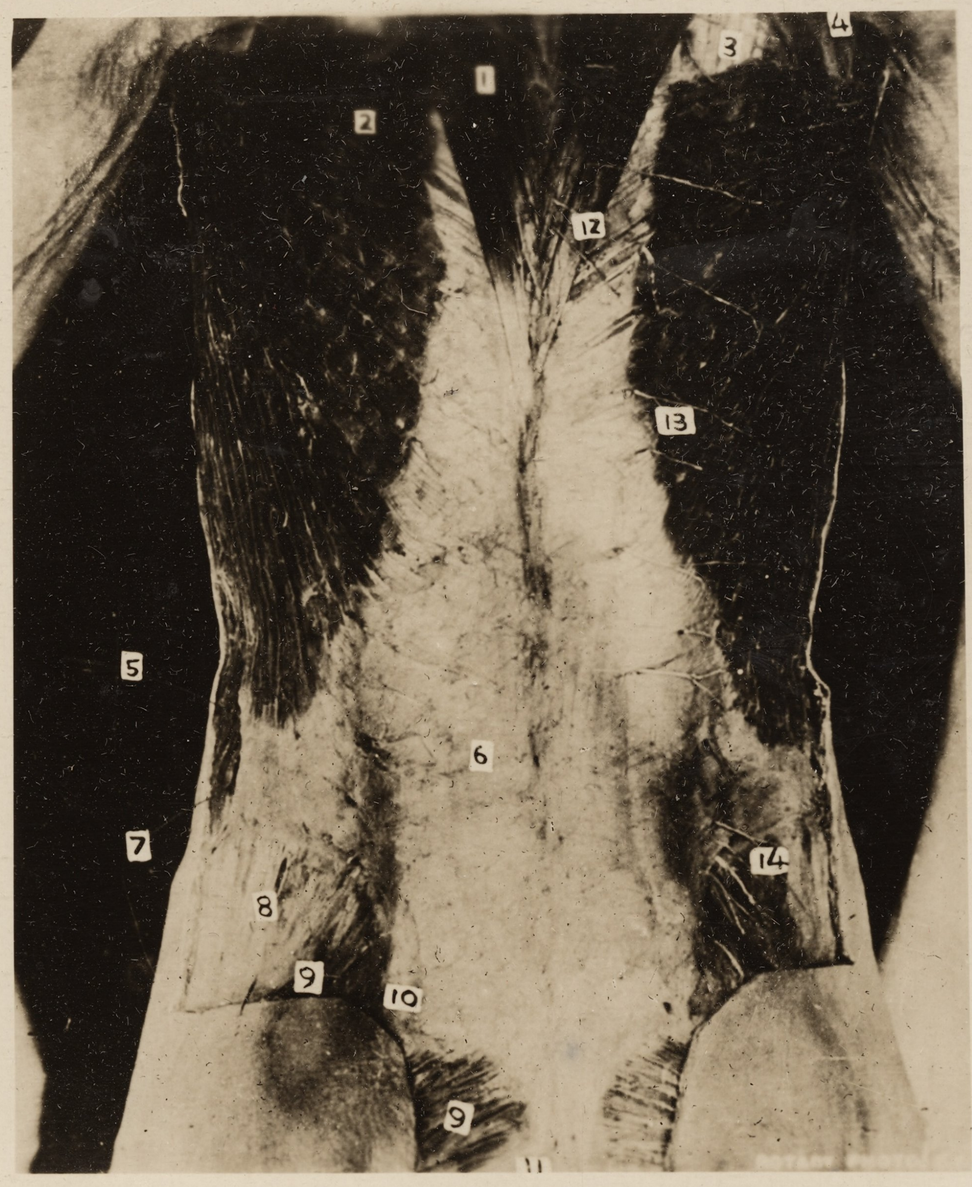

SECTION V CARD NO. 25