ABDOMEN.

ABDOMINAL AORTA—No. 1.

TO SHOW THE ABDOMINAL AORTA, THE BED OF KIDNEYS, ETC.

The kidneys, the upper parts of the ureters, the ovarian vessels, and a portion of the inferior vena cava have been removed, to show the bed of the kidneys, the gangliated cord of the sympathetic, and the branches of the lumbar plexus in relation to the psoas muscles.

The three principal foramina in the diaphragm are seen, the *oesophageal* to the left side, the *aortic* in the mesial plane and lowest, while the *inferior caval opening* is to the right and is the highest of the three.

The *bed of the kidneys* is seen to be formed by the diaphragm above, the crus of the diaphragm and the psoas muscle internally, and the quadratus lumborum and tendon of the transversalis abdominis externally.

The *abdominal aorta* enters the abdomen under cover of the ligamentum arcuatum medium of the diaphragm, and runs down in front of the vertebral column as far as to the fourth lumbar vertebra, where it terminates by dividing into the two common iliac arteries. The *coeliac axis* and the *superior mesenteric* arteries are seen arising from the commencement of the aorta and, from its anterior aspect, lower down the *inferior mesenteric.* The *middle sacral* which arises from the posterior aspect of the aorta is seen between the two common iliacs. Some *lumbar* branches, which arise rather from the posterior aspect are also seen.

The figures indicate—

1. Oesophagus.
2. Ligamentum arcuatum medium.
3 and 4. Left and right renal vessels.
5. Inferior mesenteric artery.
6. Right common iliac artery crossing the left common iliac vein.
7. Ureters crossing the common iliac arteries.
8. Gangliated cord of the sympathetic.
9. Last dorsal (subcostal) nerve.
10. Ilio-inguinal and ilio-hypogastric nerves.
11. External cutaneous nerve.
12. Accessory nerve to the external cutaneous nerve.
13. Genito-crural nerve. There is a well-marked psoas minor muscle here also.
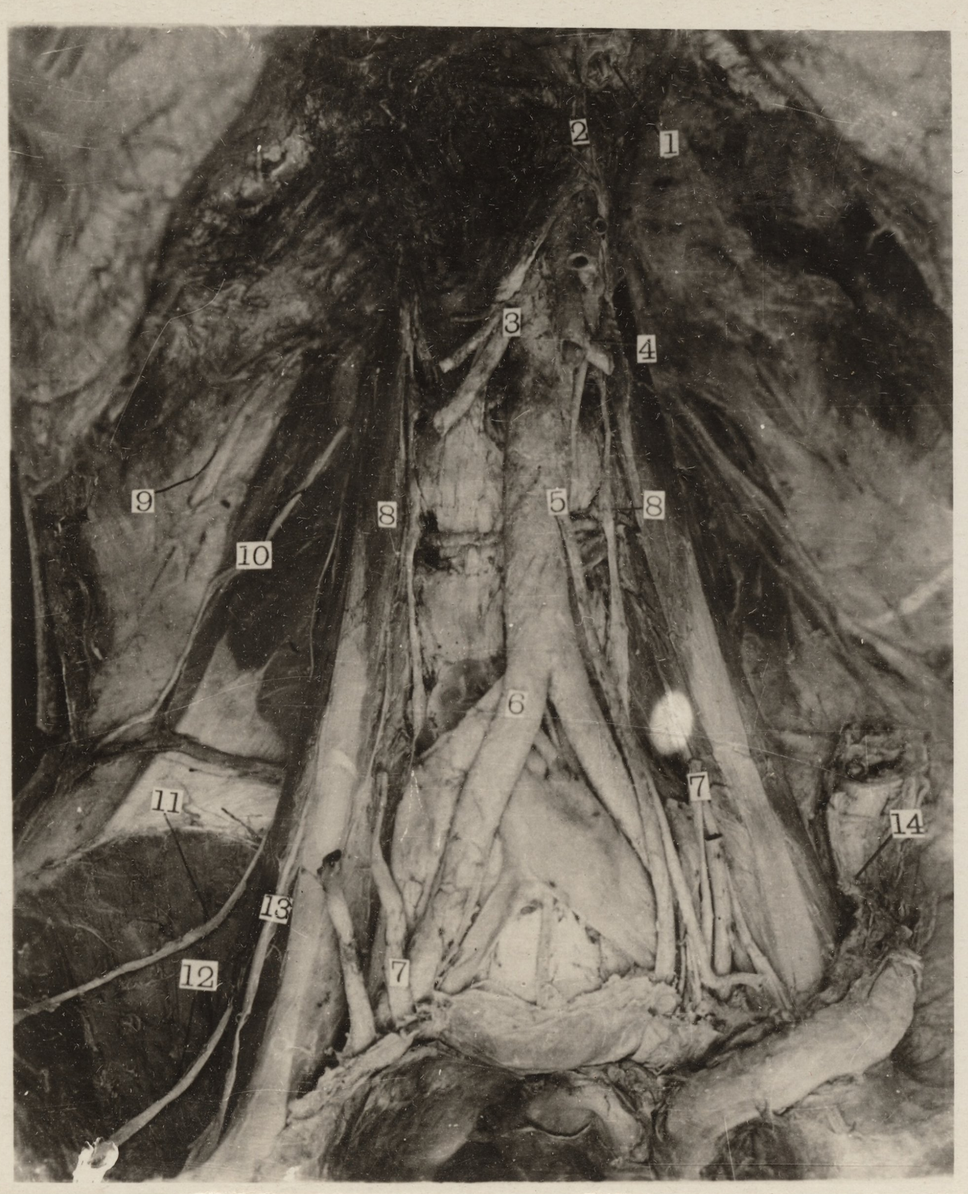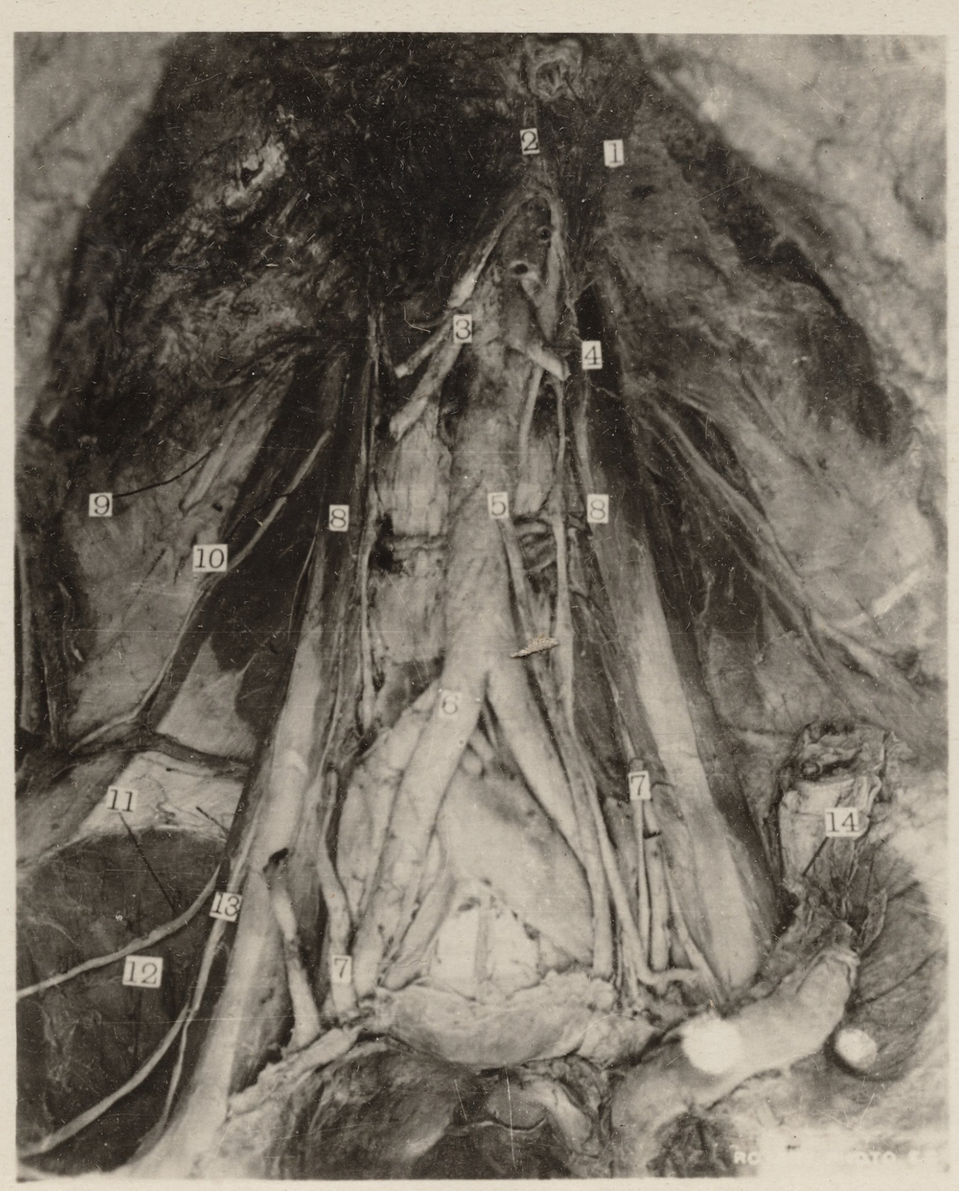
SECTION V CARD NO. 15