# ABDOMEN.

## ABDOMINAL CAVITY.—No. 8.

### SUPERFICIAL VIEW OF THE ABDOMINAL AND THORACIC VISCERA IN SITU.

This view shows a condition of the hollow abdominal viscera which is found in a large number of cases.

The condition is as follows:—The stomach is well filled, but retains an almost horizontal direction, and it is bounded by the liver on the right side, the diaphragm above and the transverse colon below. The greater curvature is almost horizontal, and looks directly forwards.

The small intestine is moderately distended, and the large intestine very considerably dilated, but the collapse of the wall shows that this distension has been largely gaseous, and not due to solid contents.

This distension has pushed the liver well up into the right hypochondriac region, so that it does not extend far beyond the mesial plane.

The transverse colon is moulded upon the under surface of the stomach, and, passing beyond it, comes into contact with the projecting lower end of the spleen, which is here of a long and narrow shape, so that its lower end can be seen from the front.

The surface of the left lung is exposed, and its shape is very typical. The pleura was somewhat adherent to the right lung.

The thymus gland projects downwards in front of the pericardium, but it is larger in this subject —a young subject, æt. six—than is usually the case in an adult.

---

***The figures indicate—***
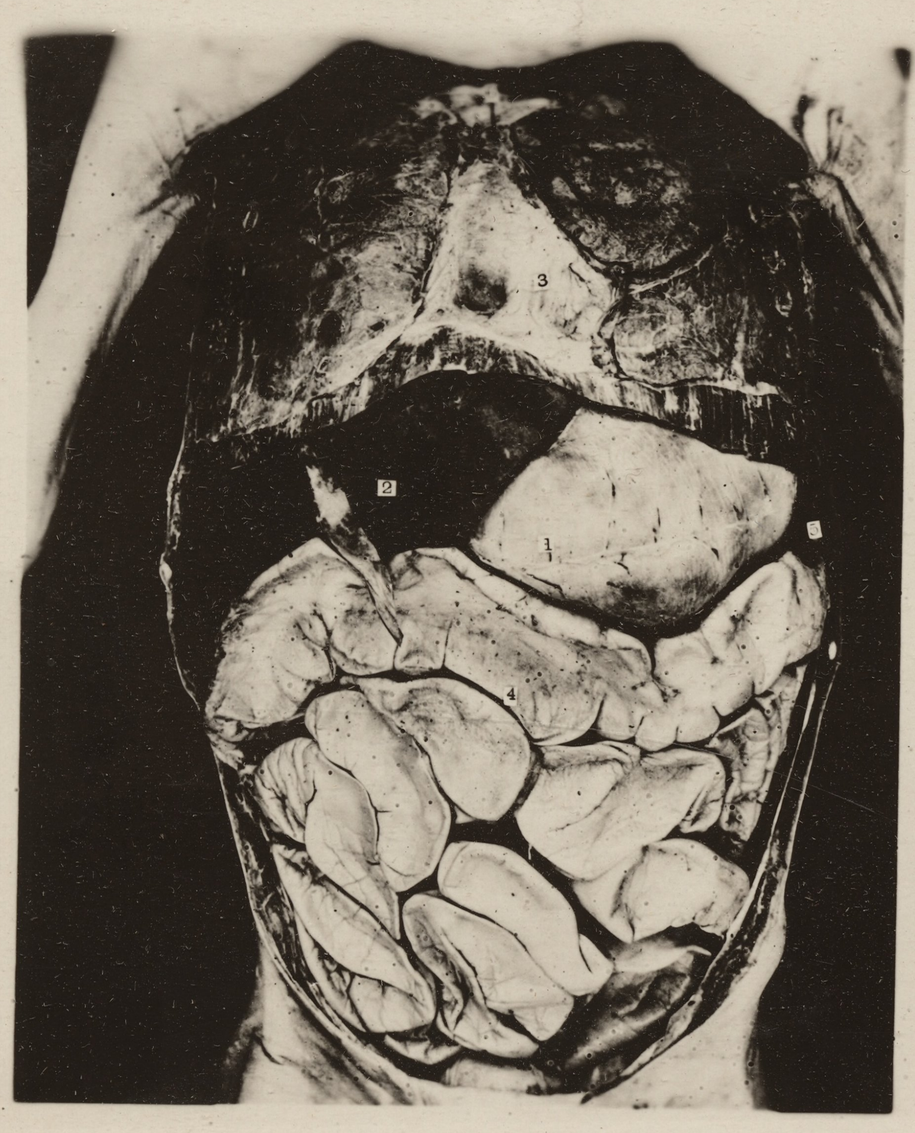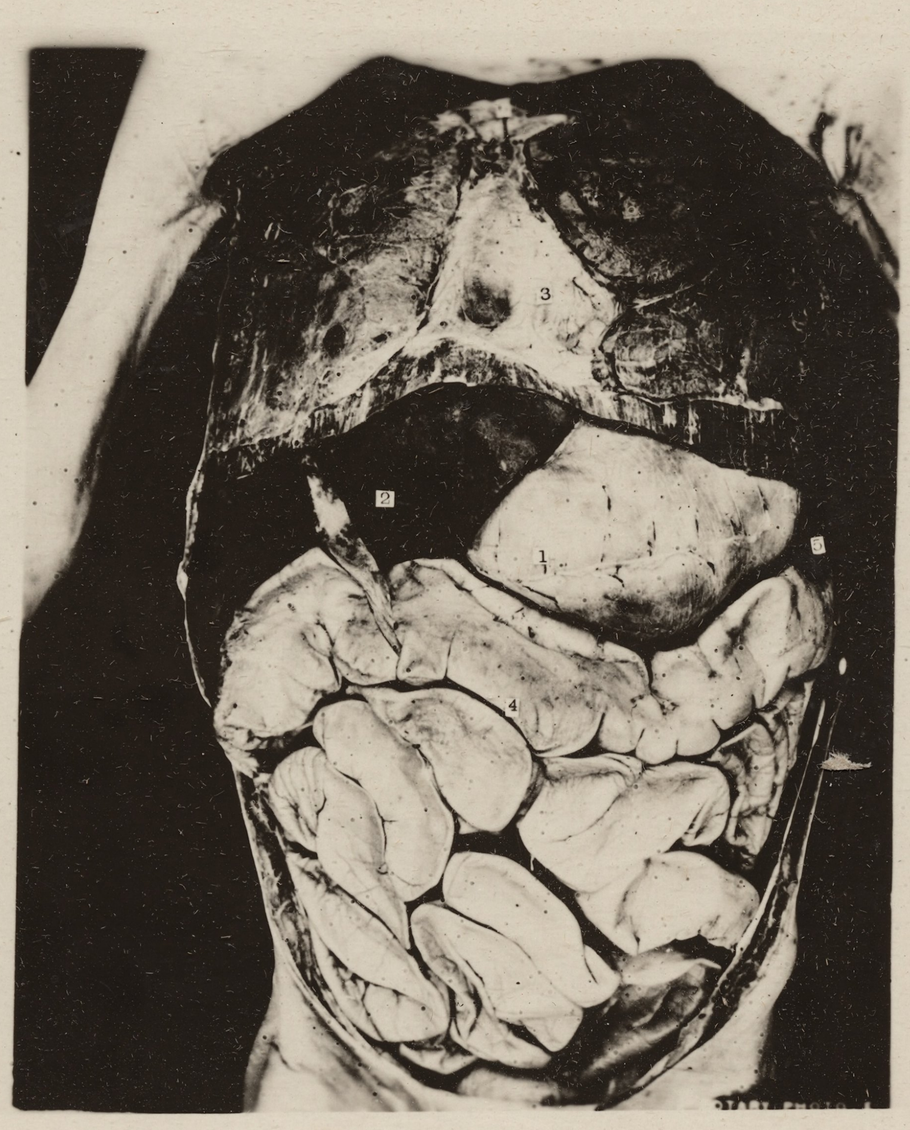
1. Greater curvature of the stomach.
2. Left lobe of liver.
3. Pericardium.
4. Transverse colon.
5. Lower end of spleen.
6. Thymus gland.