ABDOMEN

ABDOMINAL WALL.—No 4.

INTERNAL OBLIQUE, TRANSVERSALIS, AND RECTUS ABDOMINIS MUSCLES.

The external oblique muscles have been reflected, and the internal oblique muscle of the left side, as well as the anterior wall of the sheath of the rectus in nearly its whole extent.

The *internal oblique* muscle arises from the outer half of Poupart's ligament, from the middle lip of the anterior two-thirds of the crest of the ilium and from the lumbar aponeurosis, and the fibres are seen passing mainly upwards and inwards to their insertion.

The lower intercostal nerves and blood-vessels lie between this muscle and the transversalis abdominis.

The course of the rectus abdominis muscle is intersected by transverse bands of fibrous tissue, usually three in number, but, as in this specimen, occasionally more numerous, and placed at the costal margin, opposite the umbilicus, and midway between these two points. These are called the lineal transversal.

The interval between the muscles of opposite sides constitutes the *linea alba*, and is composed of fibrous tissue. It is widest above the umbilicus, and, below that level, the muscles of opposite sides gradually approach one another and come into contact, so that difficulty may be experienced in finding the interval between them.

The figures indicate—

1. Pectoralis major muscle.
2. Rectus abdominis.
3. Insertion of rectus.
4, 5, 6, and 7. Tendinous intersections of the rectus.
8. Anterior sheath of rectus, divided.
9. Divided edge of internal oblique.
10. Transversalis abdominis muscle.
11. Round ligament of uterus in the inguinal canal.
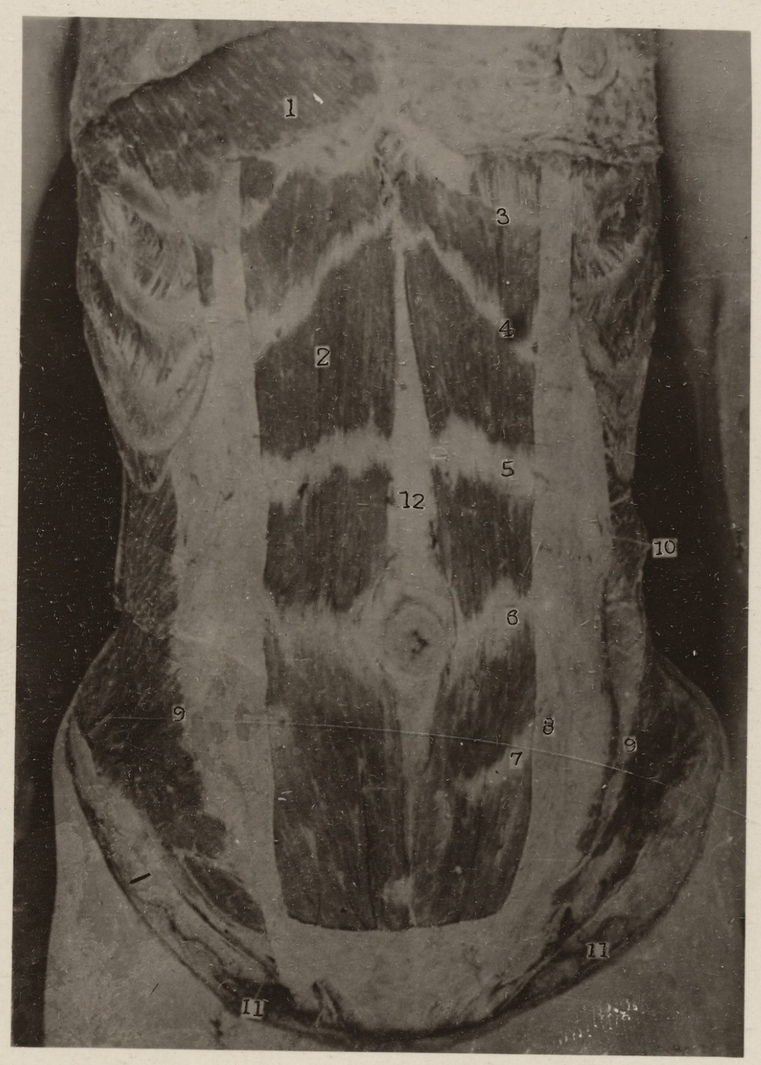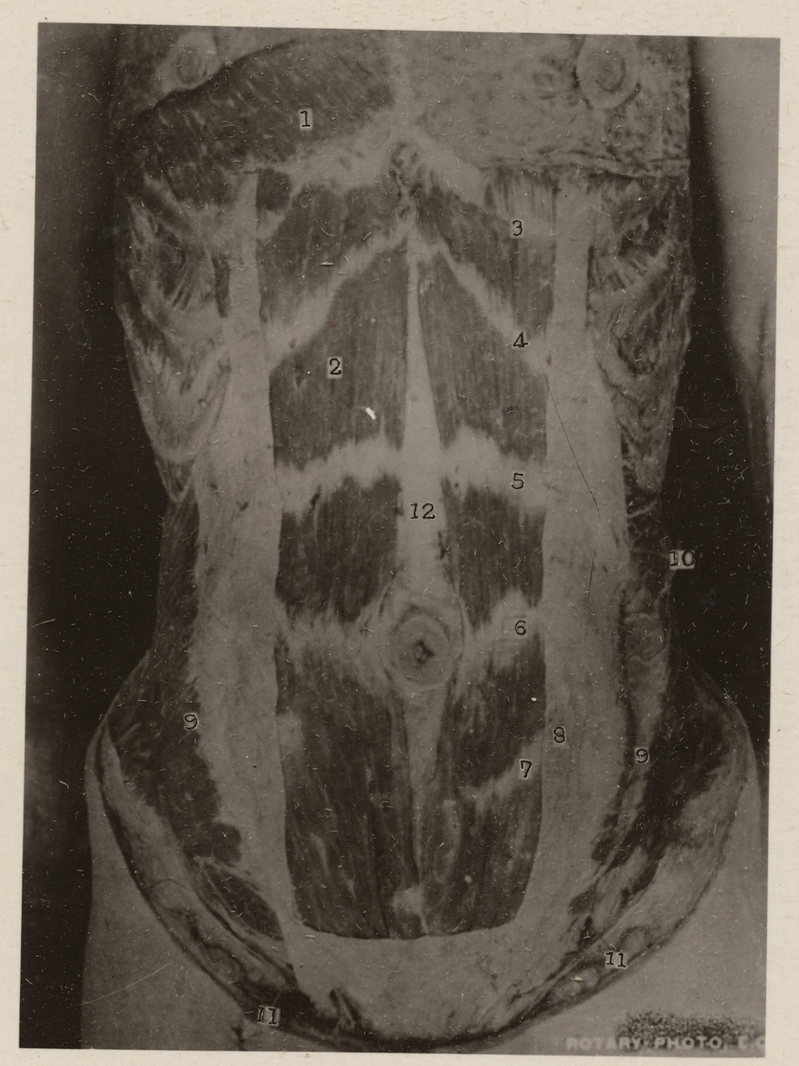
SECTION V CARD NO. 4.