# UPPER LIMB.

## ARTICULATIONS—No. 1.

### LIGAMENTS OF THE SHOULDER AND ELBOW-JOINTS SEEN FROM THE FRONT. THREE SPECIMENS.

**A.** Attached to the coracoid process are the coraco-humeral, coraco-acromial, and coraco-clavicular ligaments. The coraco-acromial ligament (3) is triangular in shape, the base is attached to the outer margin of the coracoid process, and the apex to the tip of the acromion. The central portion is weak, and sometimes, as here, shows a triangular aperture. The outer part overlies the capsular ligament of the shoulder, from which it is separated by a bursa.

The coraco-humeral ligament (4) lies at a deeper level, and passes from the root and outer border of the coracoid process to the tuberosities of the humerus, blending with the capsular ligament.

The acromio-clavicular capsular ligament (2) consists of short strong fibres, which do not require special description. The coraco-clavicular ligament (1) is in two bands—of which the anterior, which is seen here, is called the trapezoid band. It passes from the root of the coracoid process to the under surface of the clavicle. The capsular ligament of the shoulder-joint (7) is a dense and strong but lax structure, attached to the scapula around the glenoid ligament internally, and to the anatomical neck of the humerus externally. Below the coracoid process, there is an aperture in it, through which the synovial membrane communicates with a bursa below the subscapularis muscle, and between the tuberosities of the humerus is another opening (8) which transmits the long tendon of the biceps muscle.

**B.** The Anterior ligament of the elbow (9) is attached, above, to the front of the humerus, above the radial and coronoid fossæ, and, below, blends with the orbicular ligament externally (11), and is attached to the tip and margins of the coronoid process of the ulna internally.

**C.** The orbicular ligament (12) surrounds the neck of the radius like a collar, and is attached to the anterior and posterior margins of the lesser sigmoid cavity of the ulna.

---

***The figures indicate ligaments and tendons as follows—***

In **A.** 1. Trapezoid band.
2. Superior acromio-clavicular.
3. Coraco-acromial.
4. Coraco-humeral.
5. Pectoralis minor.
6. Coraco-brachialis and biceps.
7. Capsular ligament of shoulder.
8. Long tendon of biceps and transverse ligament.

In **B.** 9. Anterior ligament of elbow.
10. Brachialis anticus.
11. Orbicular ligament.
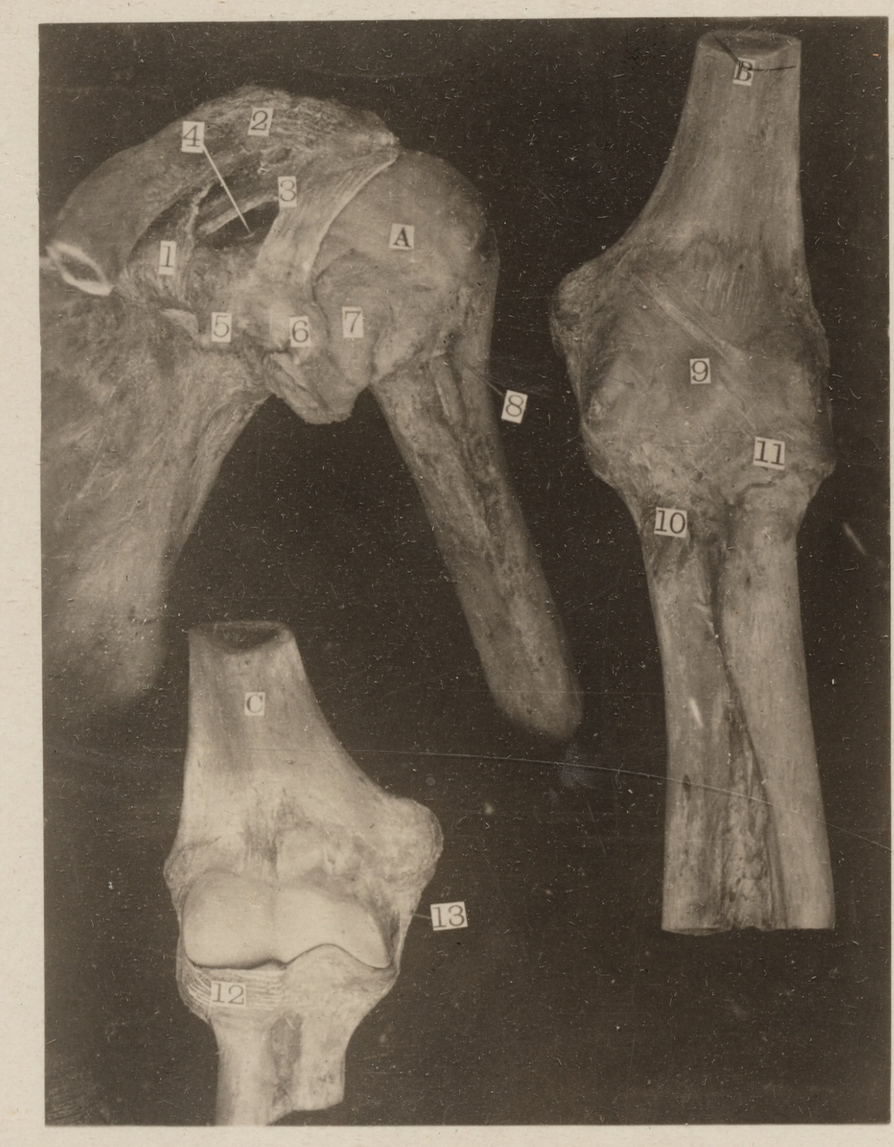
In **C.** 12. Orbicular ligament.
13. Internal lateral ligament of elbow.