UPPER LIMB.

ANTECUBITAL FOSSA—No. 2.

THE STRUCTURES FORMING THE ROOF OF THE SPACE HAVE BEEN REMOVED, THE BICIPITAL FASCIA BEING LEFT, AND THE STRUCTURES CONTAINED WITHIN IT HAVE BEEN EXPOSED.

The bicipital or semilunar fascia is a strong band of deep fascia, which passes from the tendon of the biceps muscle to the fascia on the inner side of the forearm, and is an important insertion for that muscle.

It crosses the brachial artery.

The lateral boundaries of the antecubital fossa are the supinator longus (brachio-radialis) on the outer side, and the pronator radii teres on the inner, while the base of the space is arbitrarily taken to be a line between the condyles.

The tendon of the biceps passes into the interior of the space, to gain its insertion into the back part of the bicipital tuberosity of the radius.

On the inner side of the biceps lie the brachial artery, with its venæ comites, and the median nerve lying to the inner side of the vessel. These latter structures are seen resting on the brachialis anticus muscle.

The brachial artery has bifurcated high up and is represented in this specimen by two vessels lying, one superficially and the other deeply, and the median nerve has crossed by passing under cover of the vessels, while more frequently it crosses the artery superficially.

These variations in the artery which are of frequent occurrence, require attention in such operations as ligature of the brachial, since both trunks must be tied.

The figures indicate—
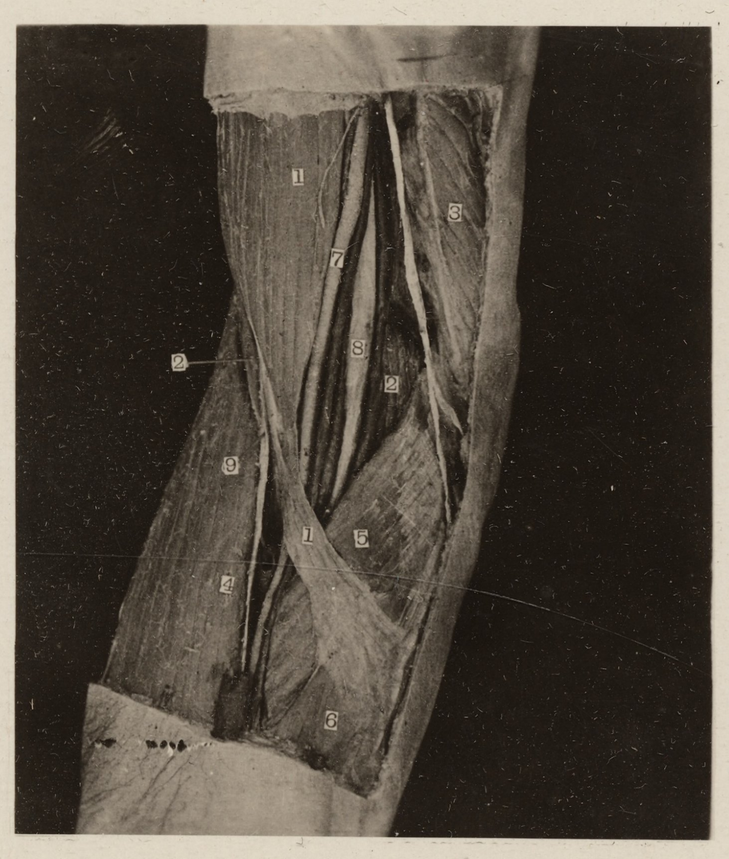
1. Bicipital fascia and biceps muscle.
2. Brachialis anticus muscle.
3. Triceps muscle.
4. Brachio-radialis muscle.
5. Pronator radii teres muscle.
6. Flexor carpi radialis muscle.
7. Brachial artery and venæ comites
8. Median nerve.
9. Musculo-cutaneous nerve.