UPPER LIMB.

SCAPULAR REGION—No. 3.

THE ACROMION PROCESS HAS BEEN REMOVED, AND THE INFRASPINATUS AND TERES MINOR MUSCLES CUT AWAY, IN ADDITION TO THE FORMER DISSECTION.

The outer head of the triceps passes up along the shaft of the humerus nearly to the great tuberosity.

The long head of the triceps is attached to the vertebral border of the scapula below the glenoid fossa, and, passing down, it intersects a triangular interval between the teres major and the teres minor, dividing it into an upper and a lower part, and the upper part is known as the quadrilateral space, and the lower as the triangular. These spaces, as will be noticed, are not present in the undissected subject except as intermuscular intervals, and can only be seen as spaces by an artificial separation.

The quadrilateral space is bounded above by the teres minor, below by the teres major, internally by the long head of the triceps, and on the outer side by the humerus, and it transmits the circumflex nerve and the posterior circumflex vessels in their course from the axilla to this region.

In the lower, or triangular space, the dorsalis scapulæ artery makes its appearance, and it winds round the border of the scapula, to be distributed principally to the infraspinous fossa.

The nerves and blood-vessels of the scapular region are arranged as follows:—

A branch of the suprascapular artery passes into the infraspinous fossa below the root of the acromion, with the termination of the suprascapular nerve, and anastomoses with the dorsalis scapulæ, and both of these vessels anastomose with the posterior scapular artery, which runs along the vertebral border, under cover of the rhomboid muscles.

The figures indicate—

1. Trapezius.
2. Supraspinatus.
3. Infraspinatus and teres minor.
4. Teres major.
5. Long head of triceps.
6. Capsular ligament of shoulder.
7. Glenoid ligament.
8. Suprascapular artery and nerve.
9. Dorsalis scapulæ artery.
10. Outer head of triceps.
11. Deltoid.
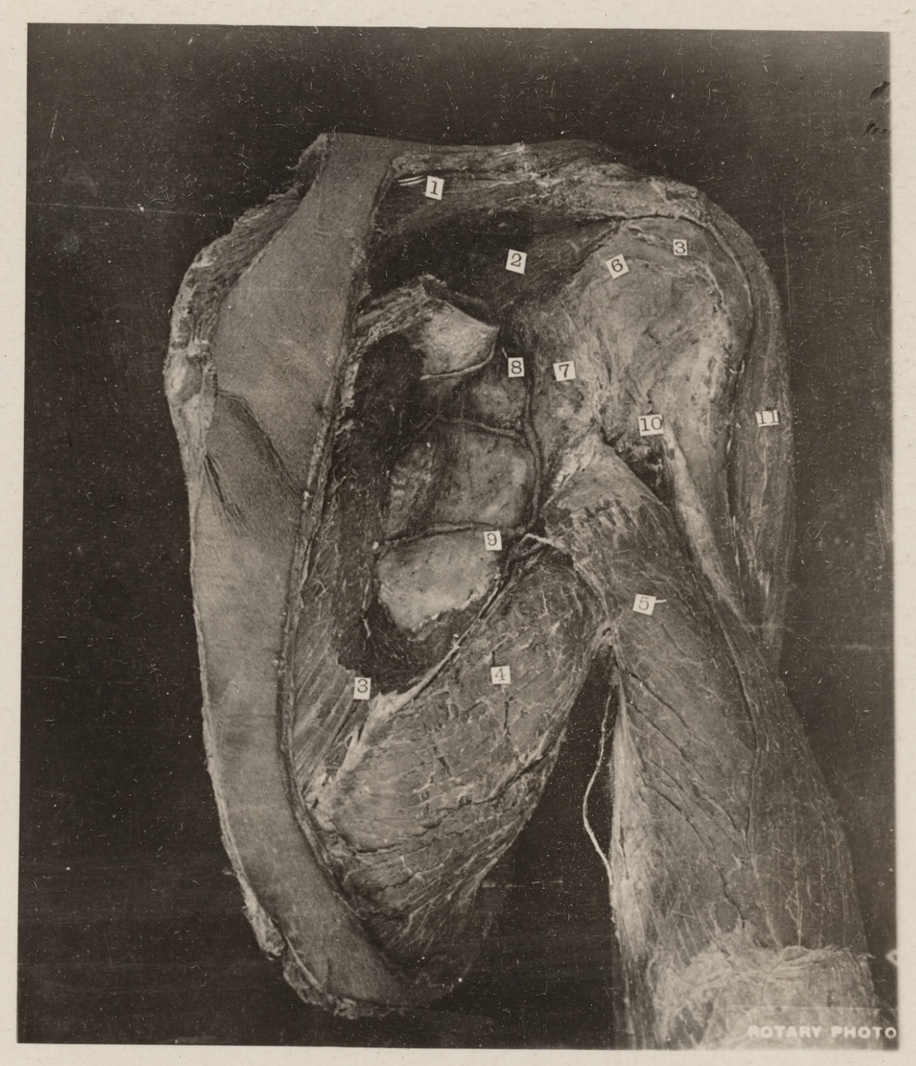
SECTION IV CARD No. 19