UPPER LIMB.

SURFACE ANATOMY—No. 1.

AXILLA AND SHOULDER FROM THE FRONT.

The region of the shoulder and upper arm is so uniformly clothed by muscles that few bony points can be made out except by deep palpation.

Thus the **coracoid process** can be felt at the outer part of the small intermuscular depression between the pectoralis major and deltoid muscles above the figure 1, and the upper part of the shaft of the humerus can be palpated along the line of the depression, between the biceps and coraco-brachialis muscles on the outer side, and the triceps on the inner, indicated by the figure 5.

The muscular structures are important and well marked.

Notice especially the rounded outline of the deltoid as it arches over the shoulder. The anterior margin of this muscle is in apposition with the upper margin of the pectoralis major, and can hardly be distinguished from it except at the attachment of the two muscles to the clavicle, where there is a small depression, already referred to.

The hollow of the axilla is bounded in front by the margin of the pectoralis major, which presents a beautiful sinuous outline, while behind, the thick rounded margin is formed by the latissimus dorsi, teres major and subscapularis muscles.

In front of these last muscles, on the inner wall of the axilla, some of the digitations of the serratus magnus muscle are distinct at their attachments to the ribs.

The outer boundary of the axilla shows the rounded belly of the biceps, while at a higher level, the coraco-brachialis is seen in the interval between the biceps and the pectoralis major. The axillary artery lies along its lower margin and runs down to the point indicated by the figure 5.

The figures indicate:—

Muscles. 1. Pectoralis major, clavicular part.
2. „ „ sterno-costal part.
3. Deltoid.

Muscles. 4. Belly of biceps.
5. Intermuscular interval over brachial artery.
6. Latissimus dorsi.

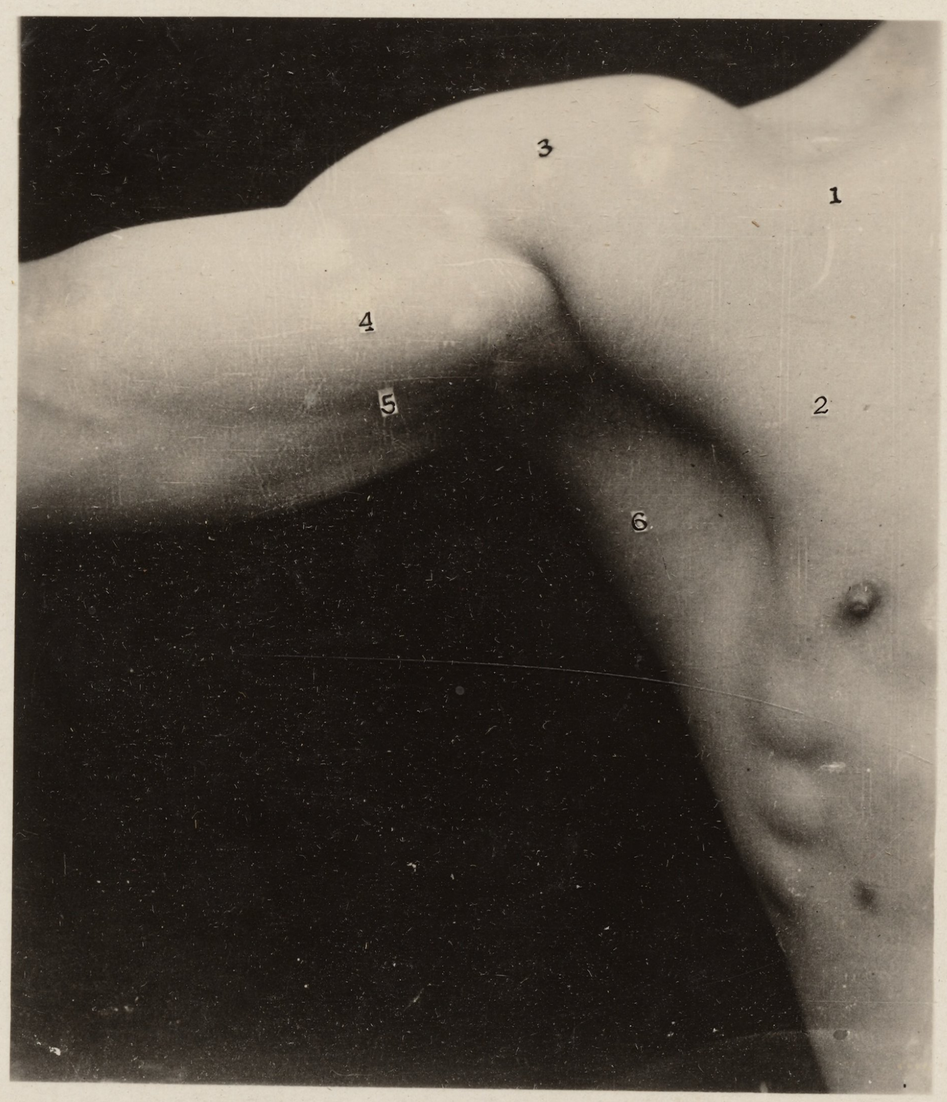

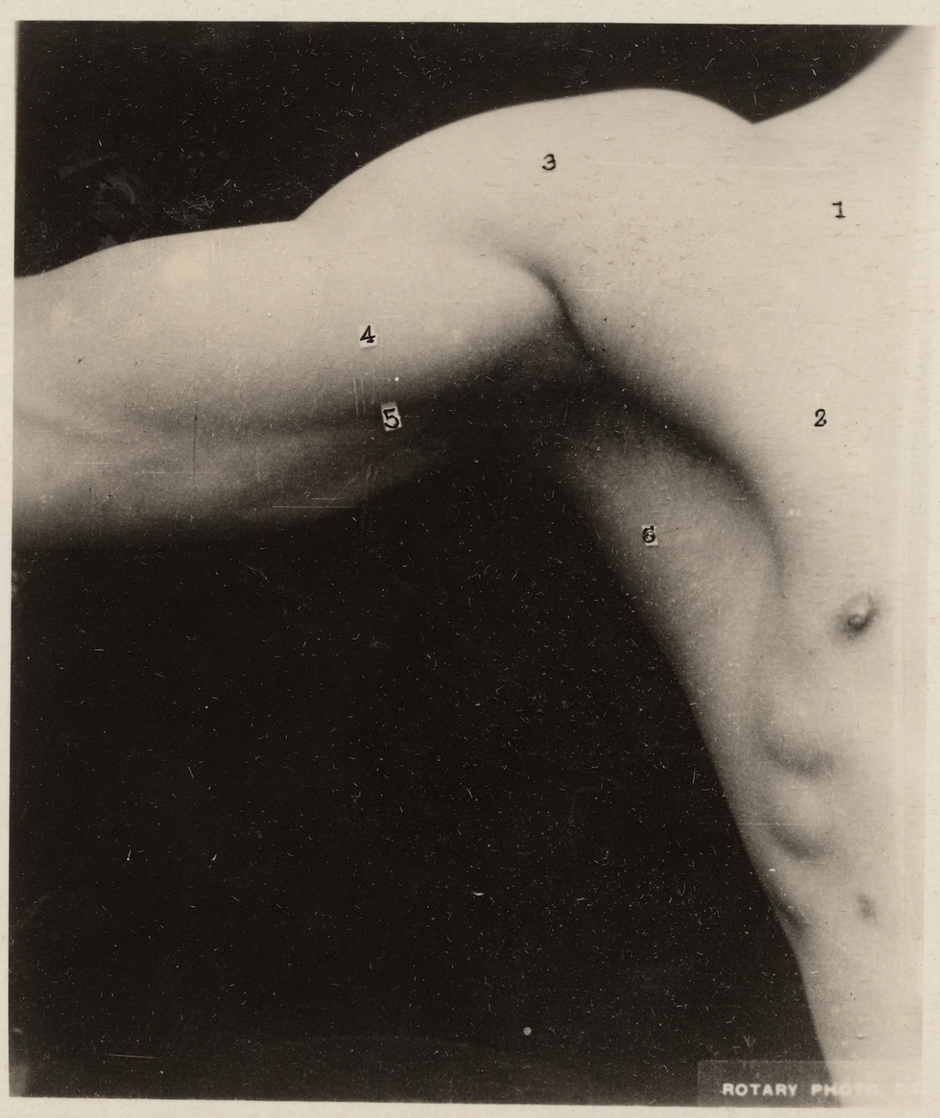

SECTION IV CARD NO. 10