THORAX.

HEART and PERICARDIUM—No 10.

BACK WALL OF THE PERICARDIUM, TO SHOW THE OPENINGS FOR THE VESSELS.

The anterior part of the pericardium has been taken away, and the heart removed by dividing the ascending aorta, the pulmonary artery just before its bifurcation, the superior and inferior venae cavae and the pulmonary veins just inside the pericardium. The internal serous layer of the pericardium is seen, lining the fibrous layer, and reflected from it upon the vessels which pierce the fibrous layer, on to the surface of the heart.

The pulmonary artery and the aorta, however, are surrounded by a common tubular sheath. The pulmonary veins of each side entered the pericardial cavity by a single aperture. The reflection of the serous pericardium extending from the inferior vena cava to the right pulmonary venous opening is seen. Notice also the bifurcation of the pulmonary artery, and its right branch passing outwards behind the ascending aorta. The groove on the left side where the pericardium passes on to the diaphragm was occupied by the great cardiac vein just before it formed the coronary sinus.

The section of the aorta shows the bulging to the right, known as the **great aortic sinus**, which simulates the commencement of an aneurismal dilatation, but is probably a normal condition since it is present in the foetus.

The figures indicate—

1. The Aorta.
2. Opening of the left pulmonary veins. The aorta can be seen lying immediately behind.
3. Pulmonary artery, at its bifurcation.
4. Superior vena cava opening.
5. Opening of right pulmonary veins.
6. Inferior vena cava opening.
7. Groove for the great cardiac vein.
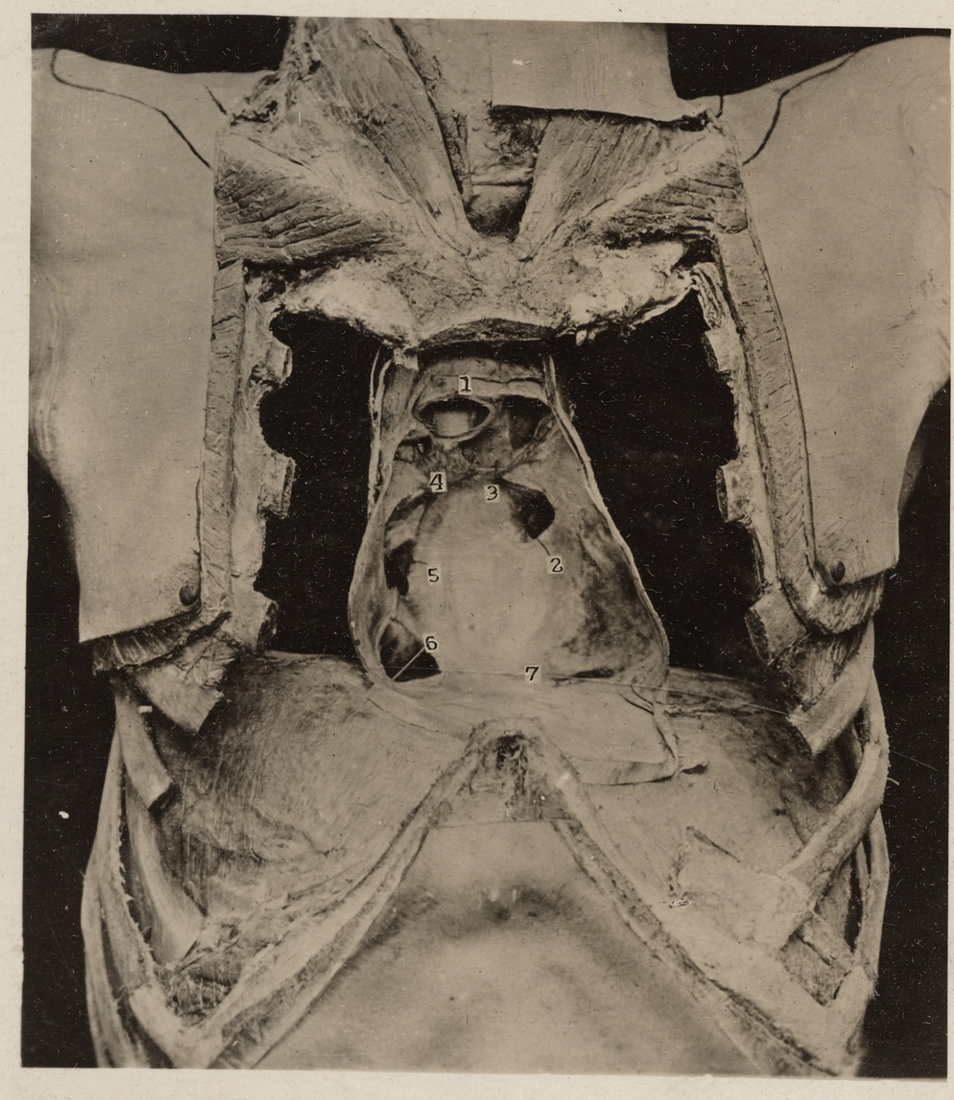
SECTION III CARD No 30