THORAX.

HEART and PERICARDIUM—No. 8.

THE INTERIOR OF THE LEFT AURICLE SEEN FROM BEHIND.

The heart and great vessels having been removed from the body, and the pericardium covering the posterior and left sides taken away, the posterior wall of the left auricle has been removed with the terminations of the pulmonary veins. The left auricle forms the greater part of the base of the heart.

It is divided into an Atrium, with smooth wall and an Appendix (3). A portion of the wall of the atrium is formed by the interauricular septum, on which is a depression, bounded below by a crescentic margin, representing the aperture of the foramen ovale in the foetus.

The Mitral orifice is placed in the front part of the floor of the chamber, and is smaller than the corresponding aperture of the right side.

Above the auricle is the bifurcation of the pulmonary artery, and the remains of the ductus arteriosus (8).

Between the pulmonary artery and the aorta a double fold of serous pericardium is present and has been opened (5).

The figures indicate—
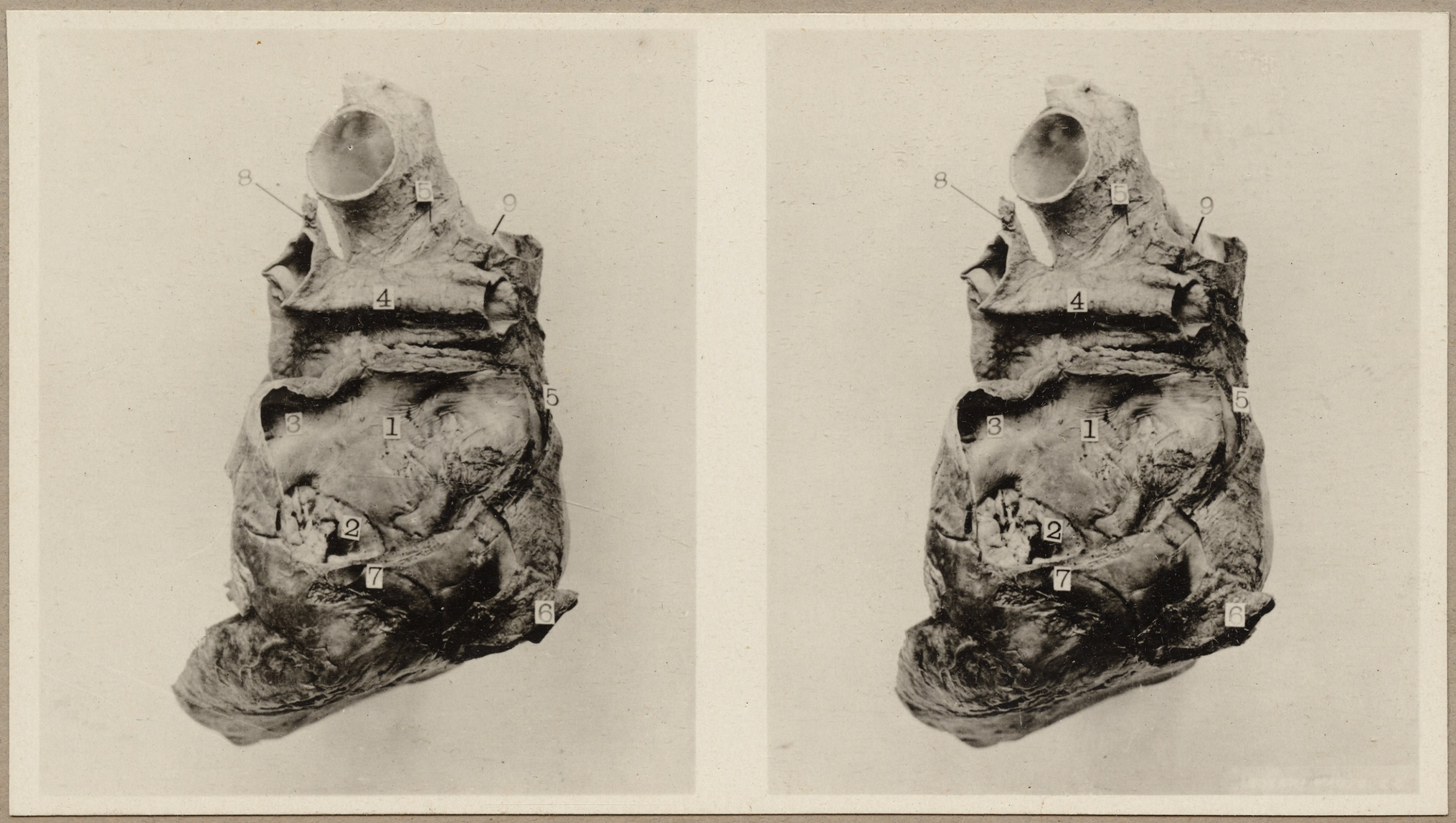
1. Septal wall of the auricle.
2. Mitral orifice.
3. Auricular appendix.
4. Bifurcation of the pulmonary artery.
5. Cavity of serous pericardium.
6. Inferior vena cava.
7. Great cardiac vein.
8. Ligamentum arteriosum.
9. Superior vena cava.