THORAX.

HEART and PERICARDIUM—No. 3.

TWO SPECIMENS VIEWED FROM THE LEFT.

The left-hand specimen (A.) shows the heart, from which the pericardium has been removed, with the great vessels, the trachea, and root of left lung.

The aorta is seen to form an arch over the root of the lung, the aortic arch lying above, and the descending thoracic aorta behind.

The left bronchus passes outwards from the bifurcation of the trachea, and joins the pulmonary vessels.

The right-hand specimen (B.) consists of the heart, aorta, and pericardium, which have been removed in one mass, and it shows the impressions on the posterior aspect of the pericardium made by the structures with which it lay in immediate contact, especially by the left bronchus and by the oesophagus on the back near the lower margin.

The redundancy of pericardium is well indicated by the wrinkles on its surface, and by the tail which projects from the region of the apex of the heart.

The figures indicate—

In both Specimens:—

1. Ascending aorta.
2. Aortic arch.
3. Left pulmonary artery.
4. Upper left pulmonary vein in the left specimen and lower vein in the right one.
5. Left bronchus and groove for it.

In A:—

6. Descending thoracic aorta behind the root of the left lung.
7. Left auricular appendix.
8. Formation of left innominate vein.

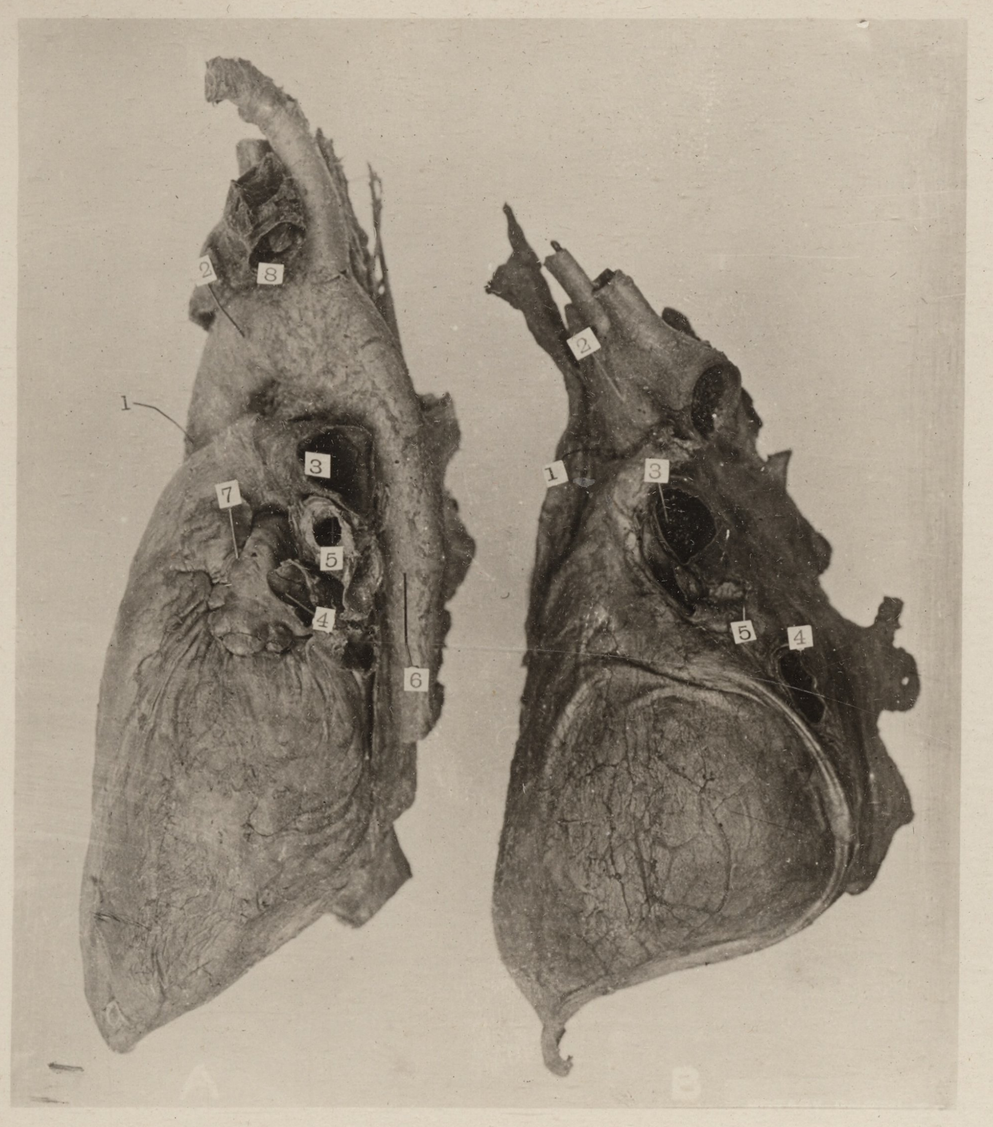

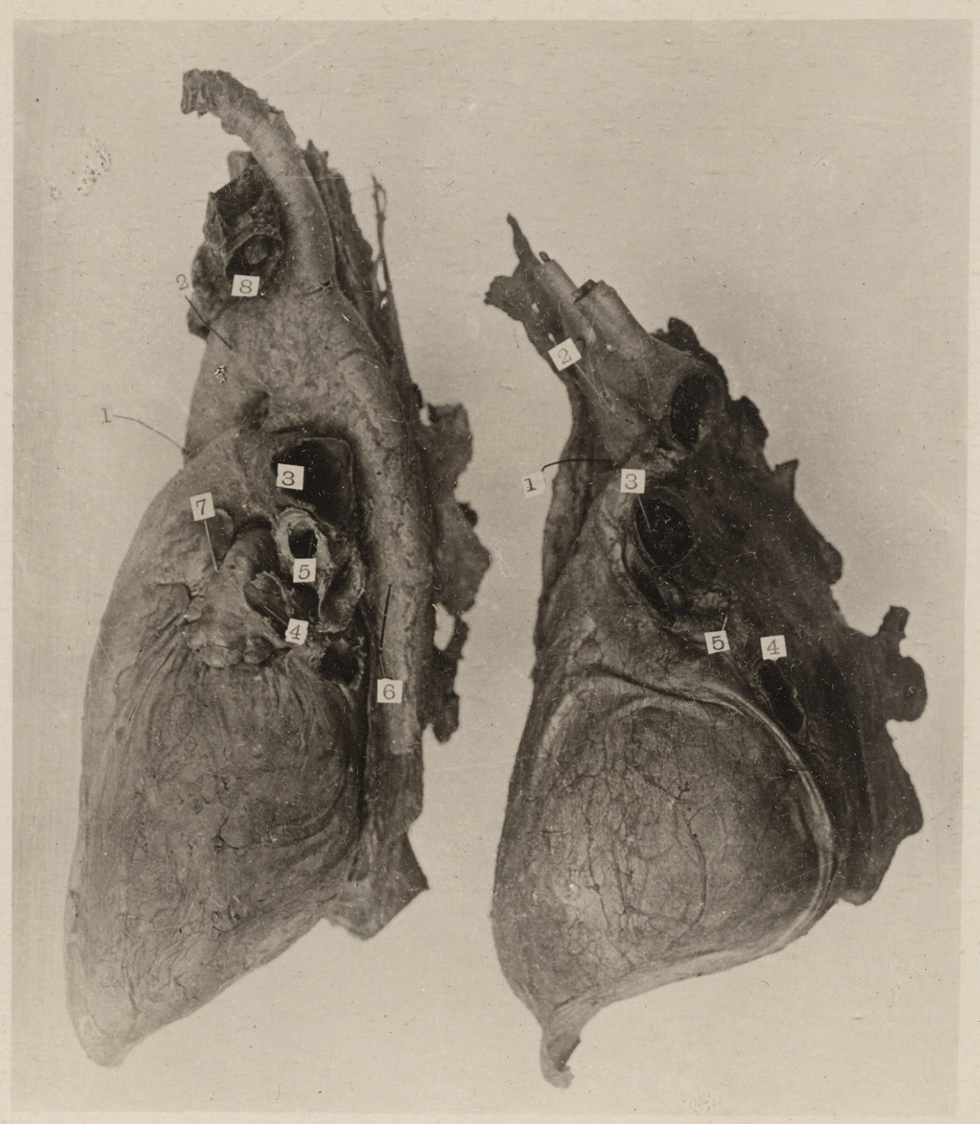

Section III Card 23