THORAX.

BACK—No. 2.

THE GREATER PART OF THE SPINE HAS BEEN REMOVED WITH PORTIONS OF THE ATTACHED RIBS, AND THE LUNGS LIFTED OUT AFTER DIVIDING THE ROOT ON EACH SIDE.

The structures shown lie mainly in the posterior mediastinum.

Aorta. The arch of the aorta, after passing backwards, reaches the vertebral column on the left side of the middle line. The aorta then passes downwards and bends slightly to the right, until it reaches the mesial plane. To its right side lies the vena azygos major, which arches forwards over the root of the right lung, and on the left side the aorta is covered by the left mediastinal pleura.

Root of the right lung. The bronchus has been divided just beyond the origin of the eparterial branch, and the eparterial and the main bronchus appear as one structure. The pulmonary veins have been divided close to their termination in the left auricle, and appear as a single vessel. The right pulmonary artery lies in front of the bronchus and between the eparterial and the main bronchus in a vertical direction.

Diaphragm. The right cupola rises rather higher than the left, and is seen to be pierced by the vena cava inferior, which then passes to the right auricle. A small part of the posterior and outer surface of this vessel lies free in the thorax, and comes into contact with the lower margin of the right lung, but the remainder of the vessel lies inside the pericardium.

Spleen. This organ is of a typical shape and size in this specimen, and its relation to the left cupola of the diaphragm should be noted.

On the right side is seen a small portion of the liver, which is not invested by peritoneum, known as the bare area of the liver. It is triangular in shape, and is bounded by the upper and lower layers of the coronary ligament.

The figures indicate—

1. Inferior vena cava.
2. Aortic arch.
3. Œsophagus.
4. Vena azygos major.
5. Root of left lung (centre of).
6. Right bronchus.
7. Right pulmonary artery.
8. Right pulmonary veins, divided at entrance to left auricle.
9. Left ventricle.
10. Liver.
11. Spleen.
12. Left kidney.
13. Aorta and margin of pleura.
14. Innominate artery.
15. Internal mammary artery.
16. Superior vena cava

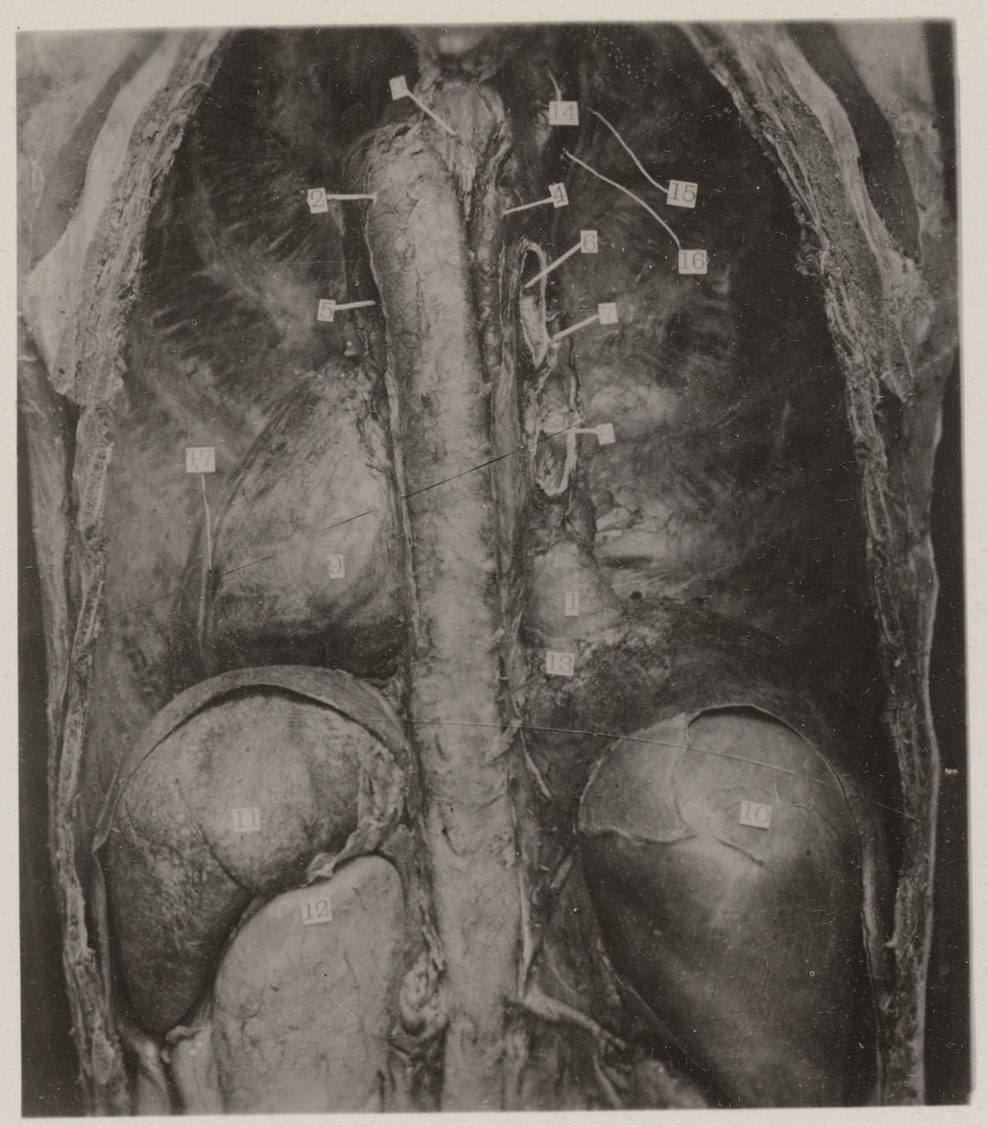

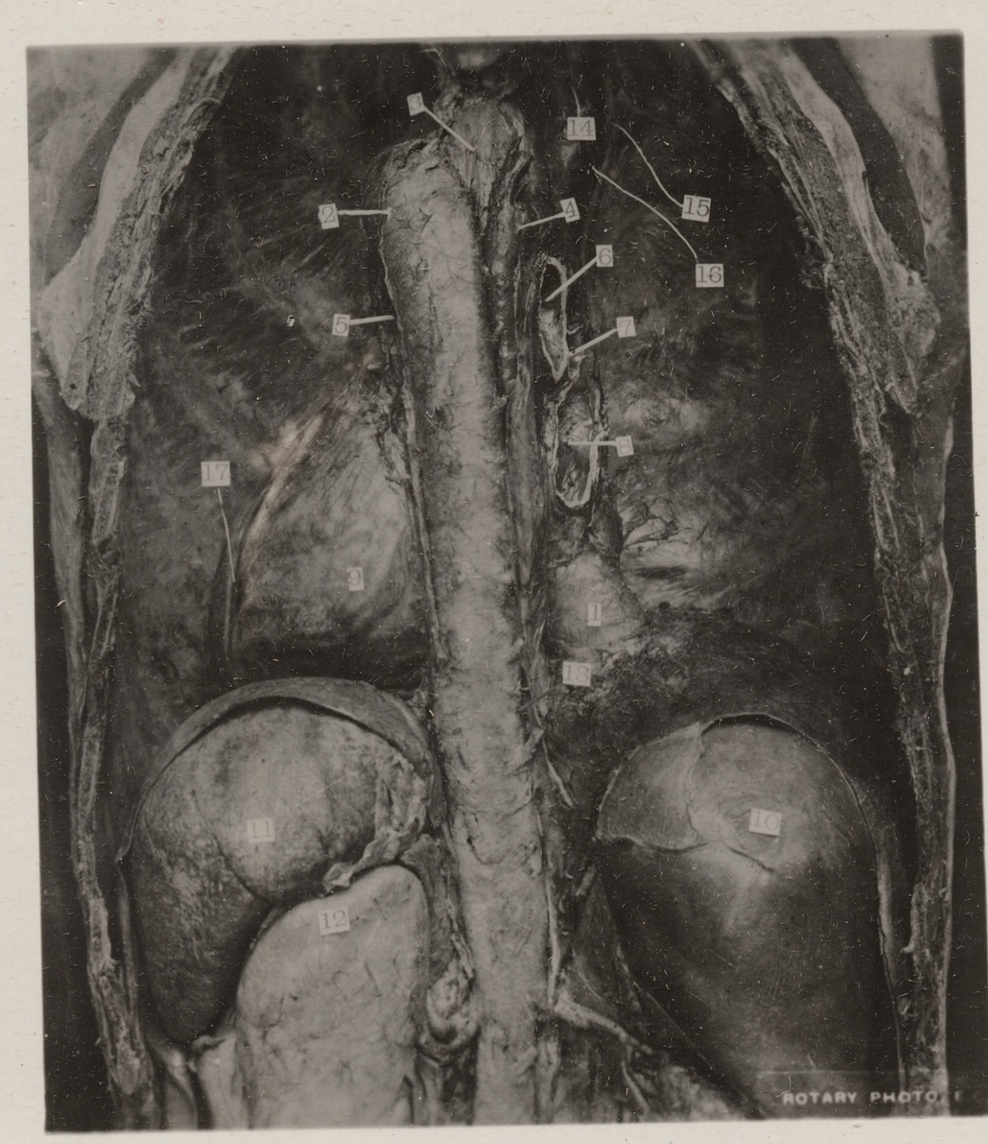

SECTION III