THORAX—No. 12.

INTERIOR OF THE RIGHT AURICLE AND VENTRICLE IN TOPOGRAPHICAL RELATION TO THE CHEST-WALL.

View from in front and slightly from the right side to show the thoracic skeleton, and, at the same time, the parts which lie under cover of it

The anterior auriculo-ventricular groove is seen to run from the middle of the sternum at the level of the third costal arch downwards and to the right, so that the cavity of the auricle lies almost entirely to the right of the sternum, while the ventricle lies behind the sternum and the inner end of the fifth right interspace.

Looking at the heart from the front, it may be said that the right auricle lies to the right of the sternum, the right ventricle occupies the area behind the sternum, and the left ventricle that to the left of the sternum.

The tip of the left auricular appendix is not seen here, but it usually appears on the left of the pulmonary artery.

The pulmonary valve lies behind the third left chondro-sternal junction, and the right auriculo-ventricular orifice behind the sternum opposite the extremity of the fourth intercostal space of the right side.

The figures indicate—
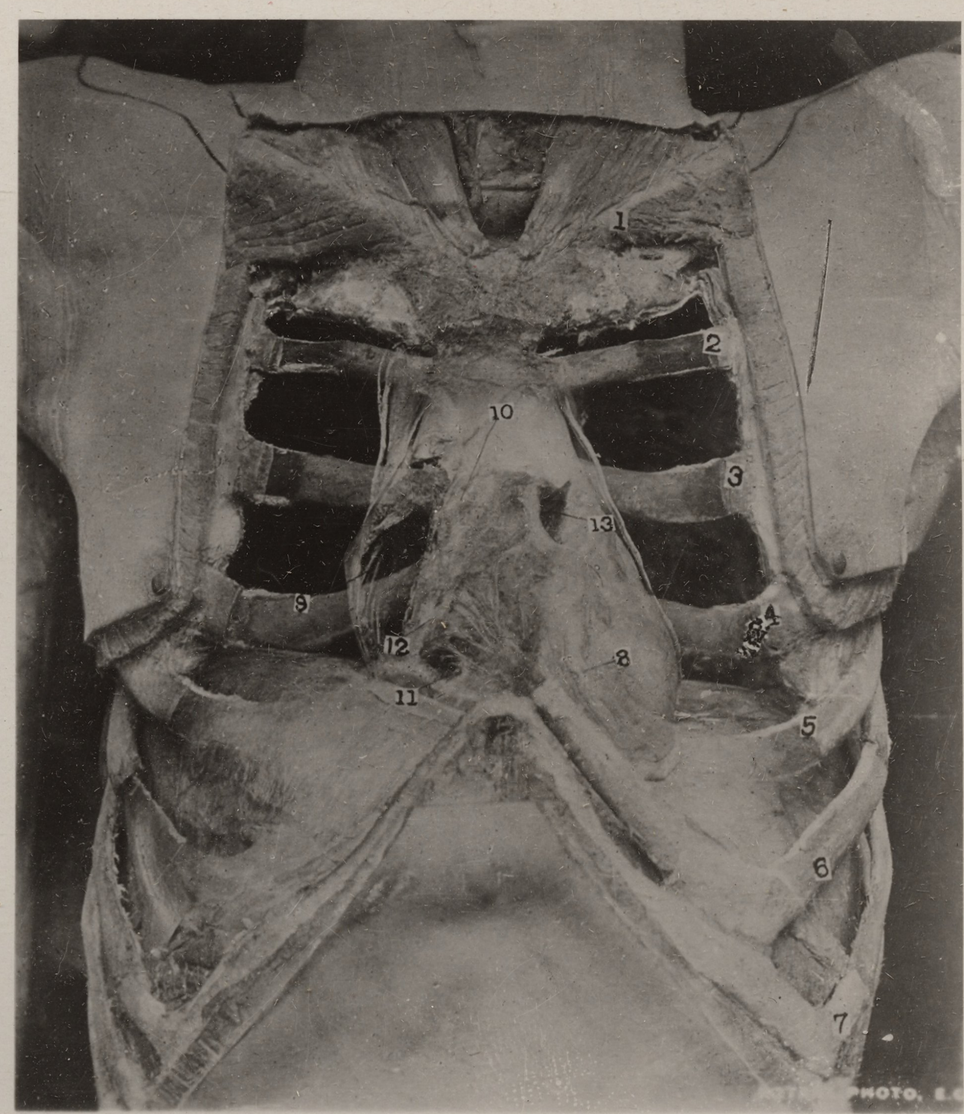
1-7. Corresponding costal arches.
8. Anterior interventricular furrow, with branch of left coronary artery.
9. Musculi pectinati of auricle.
10. Right coronary artery.
11. Anterior papillary muscle of ventricle.
12. Infundibular cusp of tricuspid valve.
13. Pulmonary valve.