HEAD AND NECK.

SPINAL CANAL—No. 3.

THE CEREBELLUM AND THE CEREBRUM HAVE BEEN REMOVED, TO SHOW THE MEDULLA OBLONGATA, MID-BRAIN, AND THE FOURTH VENTRICLE IN SITU.

The spinal cord becomes continuous with the medulla oblongata at the level of the foramen magnum. The central canal of the spinal cord is continued onwards for a short distance in the substance of the medulla, and then opens on its posterior surface, and widens out to form a cavity, which constitutes the fourth ventricle.

The floor of the fourth ventricle is formed in the lower part by the back of the medulla, and in the upper by the back of the pons Varolii. The floor is somewhat lozenge-shaped, and the lateral boundaries are formed by the superior peduncles of the cerebellum above, and below by the restiform body, the cuneate tubercle, and clava on each side.

The floor is divided into two lateral halves by a mesial furrow, and its lower end, between the two clavæ is called the calamus scriptorius. From the mesial groove near its centre some fibres emerge and run transversely outwards, called the striæ acousticæ. These divide each lateral half into an upper and a lower part. In the upper part on each side, close to the median groove, is an elevation called the fasciculus teres.

The mesial groove traced upwards leads to the aperture of the aqueduct of Sylvius, by which the cavity of the fourth communicates with the third ventricle of the brain.

On the posterior aspect of the medulla, the postero-mesial tract of the spinal cord forms a distinct elevation, called the clava, corresponding to the subjacent nucleus gracilis, and external to it is another prominence, called the cuneate fasciculus and cuneate tubercle, corresponding to the nucleus of the postero-lateral column of the cord or nucleus cuneatus, while still further out is the tubercle of Rolando. The upper part of the posterior area of the medulla passes into the inferior peduncle of the cerebellum, and is called the restiform body. The **spinal accessory nerve** arises from the side of the spinal cord and medulla as far down as to the sixth cervical segment by a series of rootlets which emerge from the side of the cord in front of the posterior roots of the spinal nerves. These rootlets join and pass up into the interior of the skull through the foramen magnum and form the nerve, which finally leaves the skull through the middle compartment of the jugular foramen.

Fourth cranial nerve. This nerve is seen arising from the dorsal aspect of the brain from a thin lamina called the valve of Vieussens, or superior medullary velum, which unites the superior peduncles of the cerebellum, below the inferior quadrigeminal bodies. The nerves then wind round the sides of the mid-brain.

---
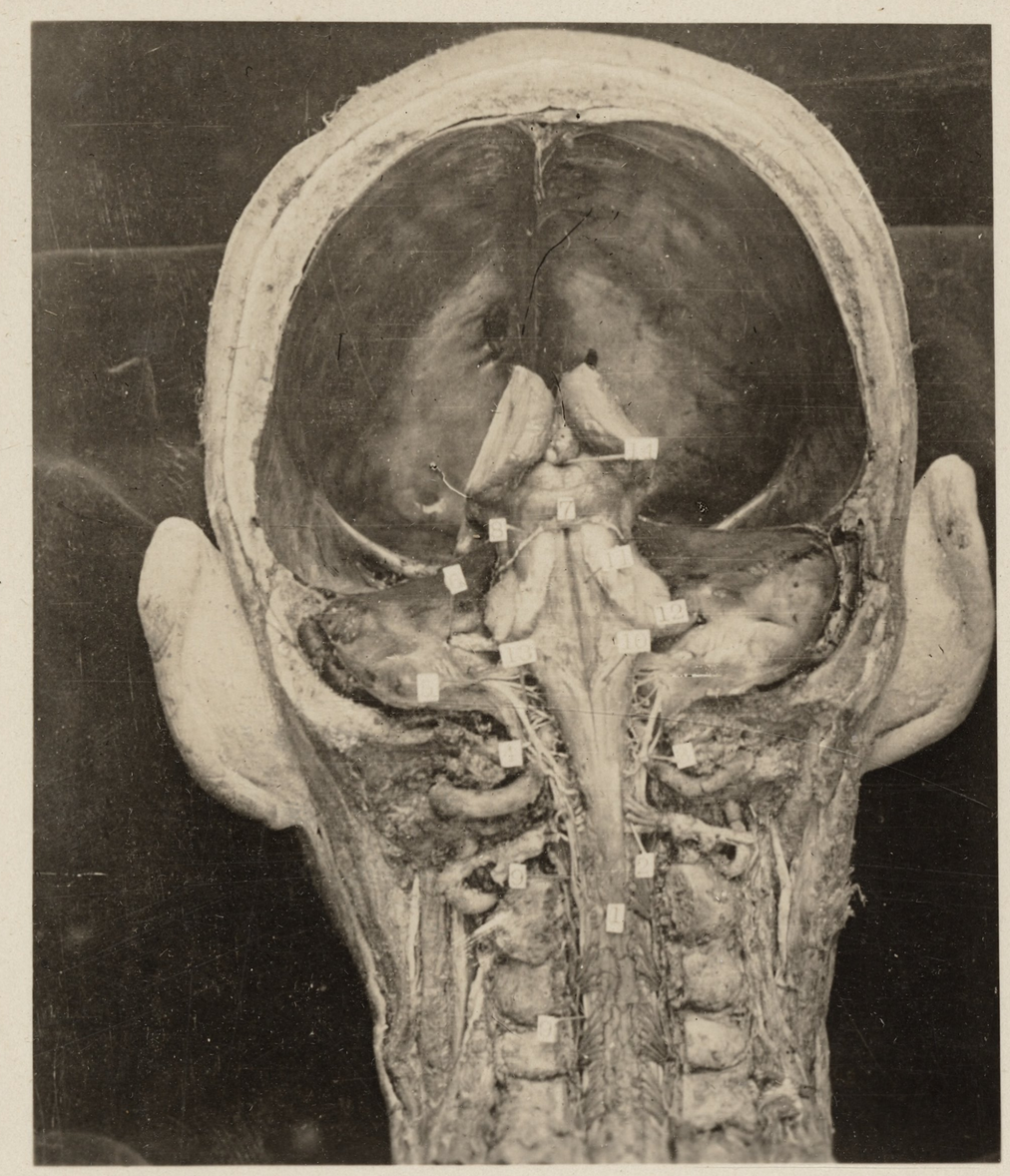
1. Spinal cord.
2. Posterior root of C II.
3. Posterior root ganglion of C I.
4. Spinal accessory crossing vertebral artery.
5. Cranial nerves IX., X., and XI.
6. Cranial nerves VII. and VIII.
7. Posterior corpora quadrigemina.
8. Fourth nerve.
9. Spinal roots of spinal accessory nerve.
10. Clava.
11. Eminentia teres.
12. Middle peduncle of cerebellum.
13. Hypoglossal nerve.
14. Pineal body.