HEAD AND NECK.

SURFACE ANATOMY—No. 1.

THE SIDE OF THE NECK IS DIVIDED BY THE STERNO-MASTOID MUSCLE INTO TWO PARTS.

In the anterior part are the following landmarks :—

1. **Hyoid bone** marks the lower limit of the floor of the mouth and of the submaxillary triangle. The lingual artery runs along its upper border, and at this level the hypoglossal nerve crosses the external carotid artery.

2. **Thyroid cartilage** with the prominent pomum Adami at its anterior angle. The common carotid artery divides opposite the upper margin of this cartilage.

3. The **cricoid cartilage** marks the lower limit of the larynx and pharynx and the commencement of the trachea and œsophagus, and lies at the level of the sixth cervical vertebra. At this level the anterior belly of the omo-hyoid muscle crosses the common carotid artery, and at the same level the artery can be compressed against the transverse process of that vertebra.

4. The anterior edge of the **sterno-mastoid muscle** itself is a distinct landmark, and overlaps the common carotid artery. The line of that artery and of the external carotid extends from the sterno-clavicular articulation to the hollow between the angle of the jaw and the front of the mastoid process.

The interval between the two heads of the muscle overlies the internal jugular vein.

Behind the sterno-mastoid is the region of the **posterior triangle** bounded behind by the anterior margin of the trapezius and below by the middle-third of the clavicle. The third part of the subclavian artery lies in the lower part of this triangle, and the artery curves downwards behind the most prominent portion of the clavicle. It can be most readily compressed by pressure downwards, backwards and inwards at a point behind the posterior border of the sterno-mastoid muscle about an inch above the clavicle.

The figures indicate—

1. Inner end of clavicle.
2. Pomum Adami.
3. Sternal head of the sterno-mastoid.
4. Clavicular head of the sterno-mastoid.
5. Hyoid bone.
6. Level of bifurcation of the common carotid.
7. Anterior border of the trapezius.
8. Clavicular portion of the pectoralis major.
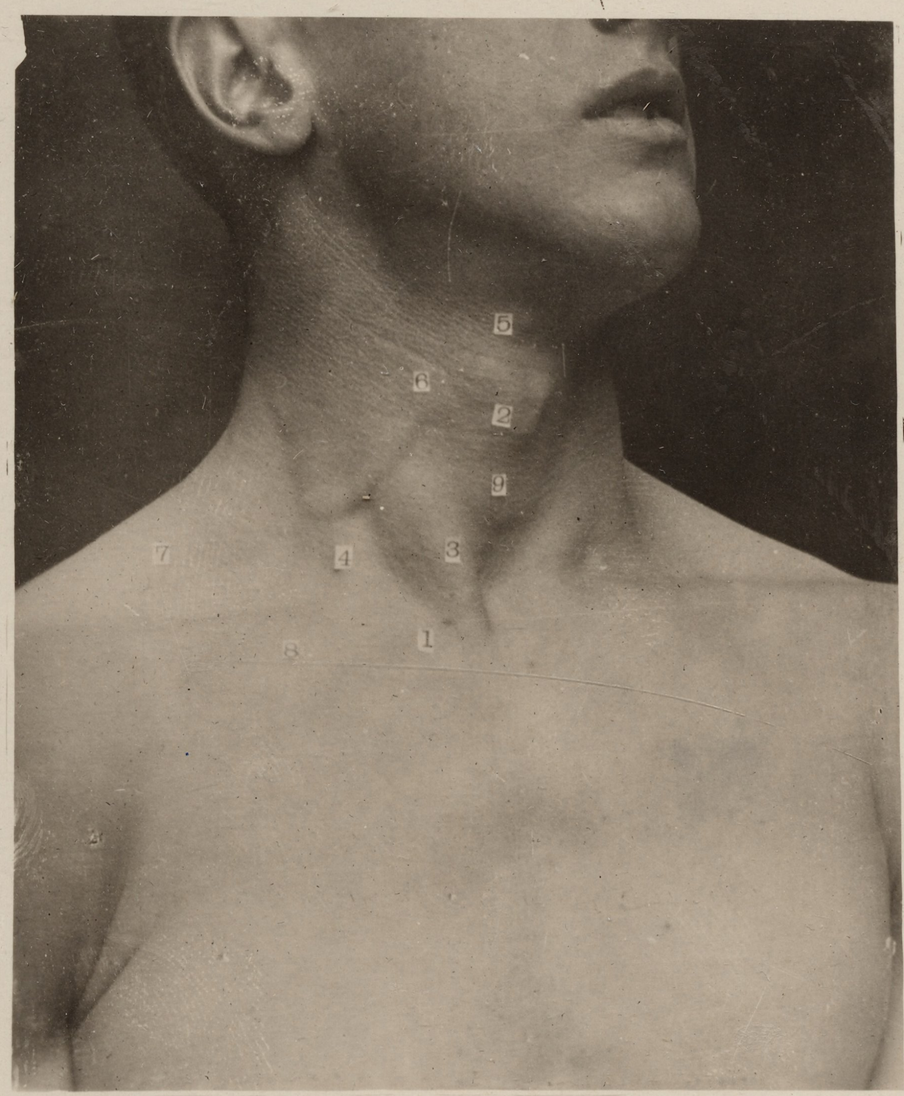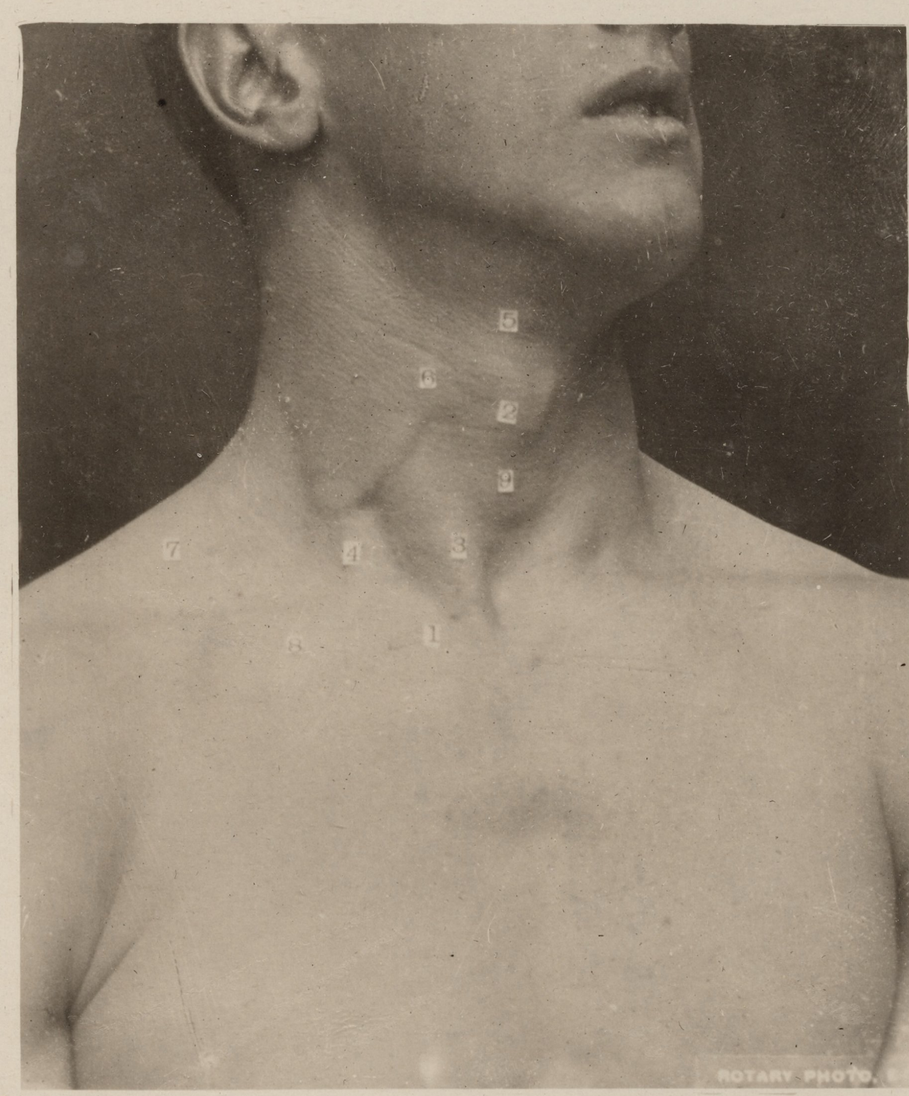
Section II Card 5