CENTRAL NERVOUS SYSTEM

BRAIN—No. 23.

DISSECTION TO EXPOSE THE MESIAL FILLET IN THE MEDULLA AND PONS.

The pyramid of the medulla and the ventral part of the pons have been removed on the left side. **Gowers' tract** has also been partly exposed.

The **mesial fillet** is a sensory tract carrying fibres from the nuclei gracilis and cuneatus of the medulla to the mid-brain and the cerebrum. The **postero-mesial** (Goll) and **postero-lateral** (Burdach) **tracts** of the cord, which are formed from the sensory posterior roots of spinal nerves, end in the **nuclei gracilis** and **cuneatus.** In these nuclei new fibres, termed **deep arcuate fibres,** arise and proceed in a transverse arcuate manner through the substance of the medulla to the middle line, where they decussate. Having decussated, most of them turn upwards and form the **fillet.** In the medulla the fillet is a flattened band, with its surfaces directed laterally, and is separated from its fellow by the median raphe only. The posterior longitudinal bundle is behind it; the pyramid is in front of it. Entering the pons it is twisted so that its surfaces look backwards and forwards. Here it lies between the ventral and the dorsal or tegmental divisions of the pons. Leaving the pons it traverses the tegmentum of the mid-brain where it gives off numerous fibres to the **superior corpus quadrigeminum,** and proceeds upwards through the sub-thalamic region to the **optic thalamus,** where many of its fibres end. The remainder pass into the **internal capsule,** and are carried by the **corona radiata** to the **Rolandic area.** Fibres are added to it from nuclei of sensory cranial nerves of the opposite side. From the cells in the corpus quadrigeminum superius and optic thalamus round which fillet fibres end new fibres proceed to the cerebral cortex.

The antero-lateral ascending cerebellar **tract** of **Gowers** begins in the lumbar region of the cord, probably arising from cells of the posterior horn. It ascends through the antero-lateral column of the cord, and lower part of medulla, dips under the olive, enters the pons and traverses its tegmentum. Reaching the upper part of the pons, it turns backwards, and is carried by the superior cerebellar peduncle and superior medullary velum to the cerebellum. A few fibres go up to the superior corpus quadrigeminum.

The figures indicate—

1. The mesial fillet in the pons.
2. Trunk of fifth cranial nerve.
3. Emerging trunk of seventh cranial nerve. The pin is closely applied to the outer side of Gowers' tract.
4. Middle cerebellar peduncle.
5. Flocculus. Between 4 and 5 is the eighth cranial nerve.
6. Olive. To its inner side is seen the anterior edge of the fillet.
7. Lower border of right half of pons.
8. Anterior part of hippocampal gyrus.
9. Cut surface of crusta of mid-brain.

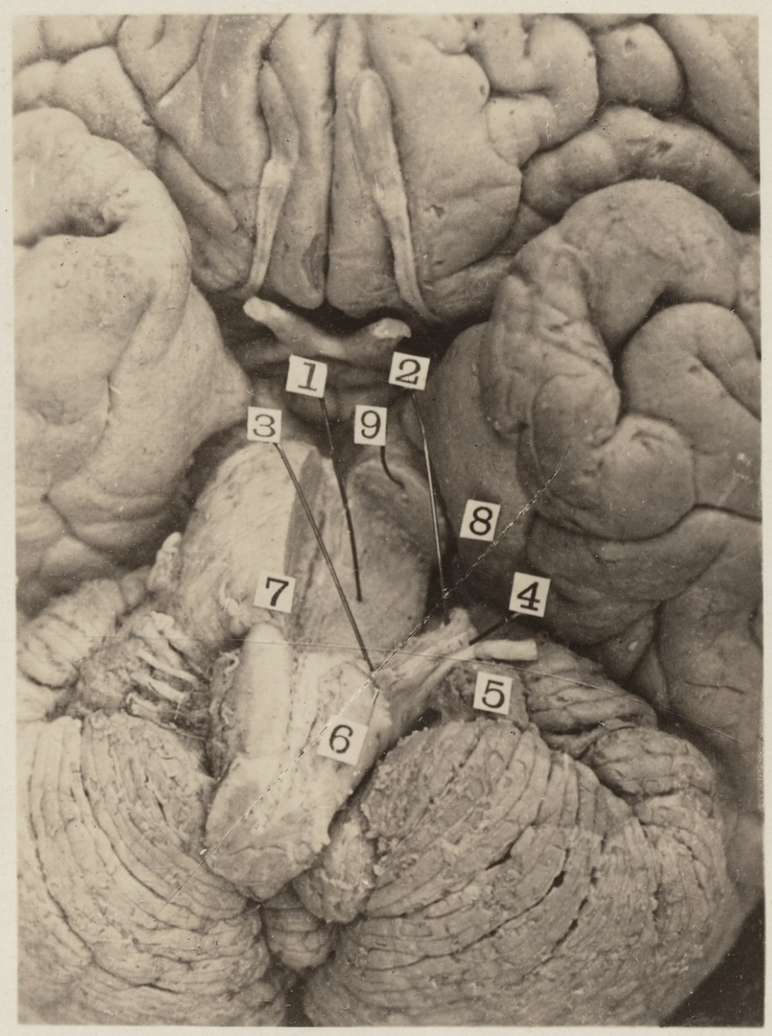

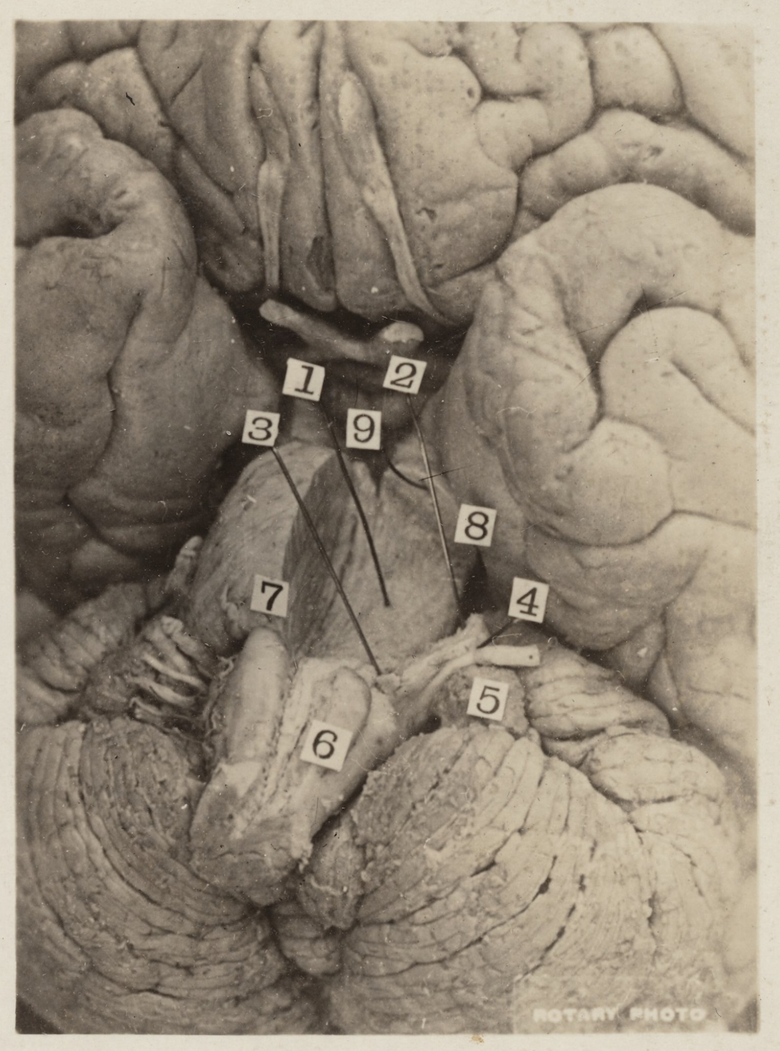

Section # Card 2