CENTRAL NERVOUS SYSTEM.

BRAIN—No. 18.

DISSECTION FROM THE UPPER AND OUTER ASPECTS OF THE LEFT CEREBRAL HEMISPHERE TO SHOW THE CORONA RADIATA AND ITS RELATIONS TO THE BASAL GANGLIA.

The brain substance has been removed, exposing the lenticular nucleus and the corona radiata from the outer side. From above the hemisphere has been sliced down to a short distance above the corpus callosum. The corpus callosum and the callosal convolution have been removed.

The **corona radiata** is composed of the great majority of 'projection' fibres, which connect the cortex cerebri with the optic thalamus, mid-brain, pons, medulla, and spinal cord. Traced downwards its fibres converge towards the basal ganglia, intersecting the fibres of the corpus callosum, and form the internal capsule, which is situated between the optic thalamus and the caudate nucleus, on its inner side, and the lenticular nucleus on its outer side. It contains the motor pyramidal tract, the fronto-pontine and temporo-pontine tracts, the auditory and optic radiations, thalamo-cortical fibres, and some fibres of the superior cerebellar peduncle and of the mesial fillet.

The fibres of the **auditory radiation** arise in the internal geniculate body, enter the internal capsule, pass outwards under the lenticular nucleus, proceed into the temporal lobe to end in the 'auditory area'—*i.e.* the middle of the upper temporal gyrus and the gyri on the insular surface of the temporal operculum.

The fibres of the **optic radiation** establish connection between the occipital cortex and the lower visual centres, in which retinal fibres of the optic tract end, viz: corpus quadrigeminum superius, pulvinar, corpus geniculatum externum. Traced from below they enter the internal capsule, and thence radiate backwards into the occipital lobe.

Thalamo-cortical fibres arise in the optic thalamus, enter the internal capsule and, through the corona radiata, are distributed to all parts of the cortex. They include fibres of the optic radiation.

The figures indicate—

1. Corona radiata.
2. Optic radiation.
3. Auditory radiation and temporo-pontine fibres.
4. Anterior white commissure.
5. Lenticular nucleus (exposed from the outer side).
6. Caudate nucleus.
7. Optic thalamus.
8. Tænia semicircularis.
9. Deep fibres of fasciculus uncinatus.
10. Temporal pole.
11. Posterior orbital gyrus. (Between 10 and 11 is the stem of the fissure of Sylvius.)
12. Calcarine fissure.

Card 28
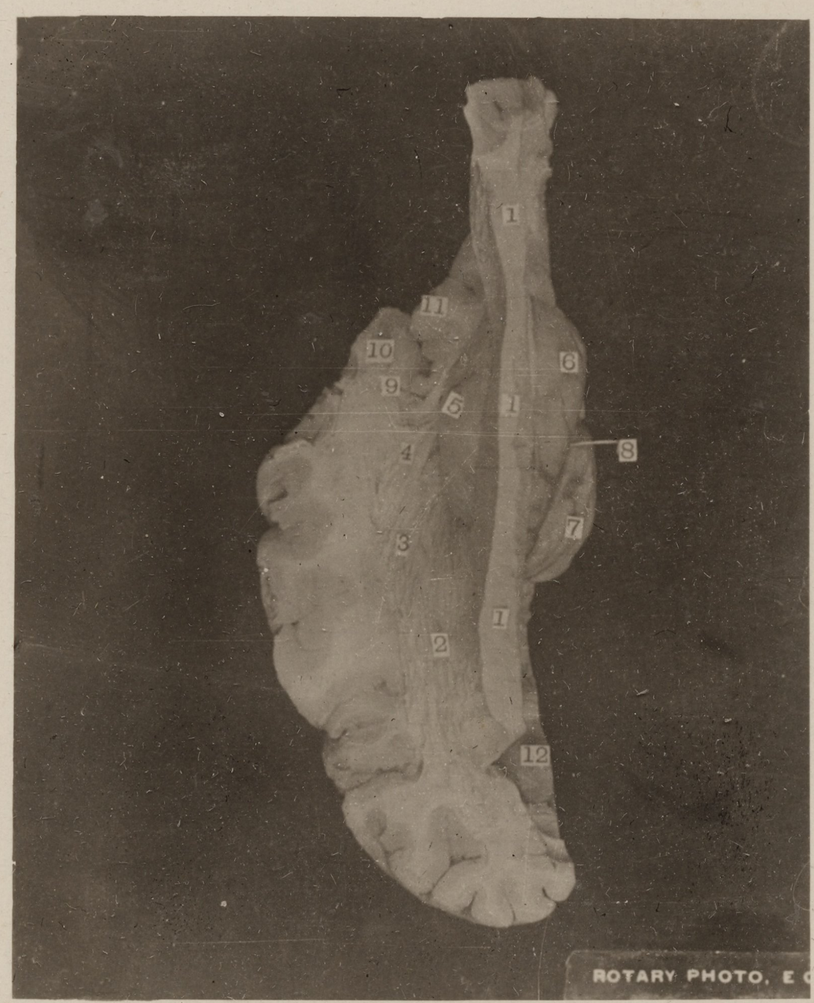
Section I