CENTRAL NERVOUS SYSTEM.

BRAIN—No. 17.

DISSECTION FROM THE OUTER SIDE OF THE LEFT CEREBRAL HEMISPHERE TO SHOW THE OUTER SURFACE OF THE LENTICULAR NUCLEUS, THE CORONA RADIATA, AND THE ANTERIOR WHITE COMMISSURE.

The opercula, the island of Reil, the claustrum, the external capsule, the anterior part of the hippocampal gyrus, and the uncus have been removed.

The **lenticular nucleus** together with the caudate nucleus forms the corpus striatum. It is placed upon the outer aspect of the internal capsule which separates it from the caudate nucleus and the optic thalamus. Laminæ of grey matter pass between the two nuclei through the internal capsule. Externally it is covered by the external capsule, the claustrum, and the island of Reil. The lower part of its anterior end is directly continuous with the caudate nucleus internally, and with grey matter of the anterior perforated spot below. Posteriorly its lower surface rests upon the anterior commissure and fibres passing between the internal capsule and the temporal lobe.

The **lenticulo-striate** and **lenticulo-optic** branches of the middle cerebral artery pass through the anterior perforated spot and ascend for a certain distance between the lenticular nucleus and the external capsule (the grooves for these are faintly indicated). They then pass inwards through the lenticular nucleus and through the internal capsule to end—the lenticulo-optic arteries in the optic thalamus, the lenticulo-striate in the caudate nucleus. The largest of the latter group is Charcot's 'Artery of cerebral hæmorrhage.'

The **anterior commissure** connects the olfactory lobes and the temporal lobes. In the middle line it is free, in front of the anterior pillars of the fornix in the anterior wall of the third ventricle. It extends outwards on either side, below the caudate nucleus and below the internal capsule, where it sends forwards a small contribution to the olfactory tract. Thence it proceeds outwards and backwards, below the lenticular nucleus and over the amygdaloid nucleus, to lose itself in the white centre of the temporal lobe.

The figures indicate—
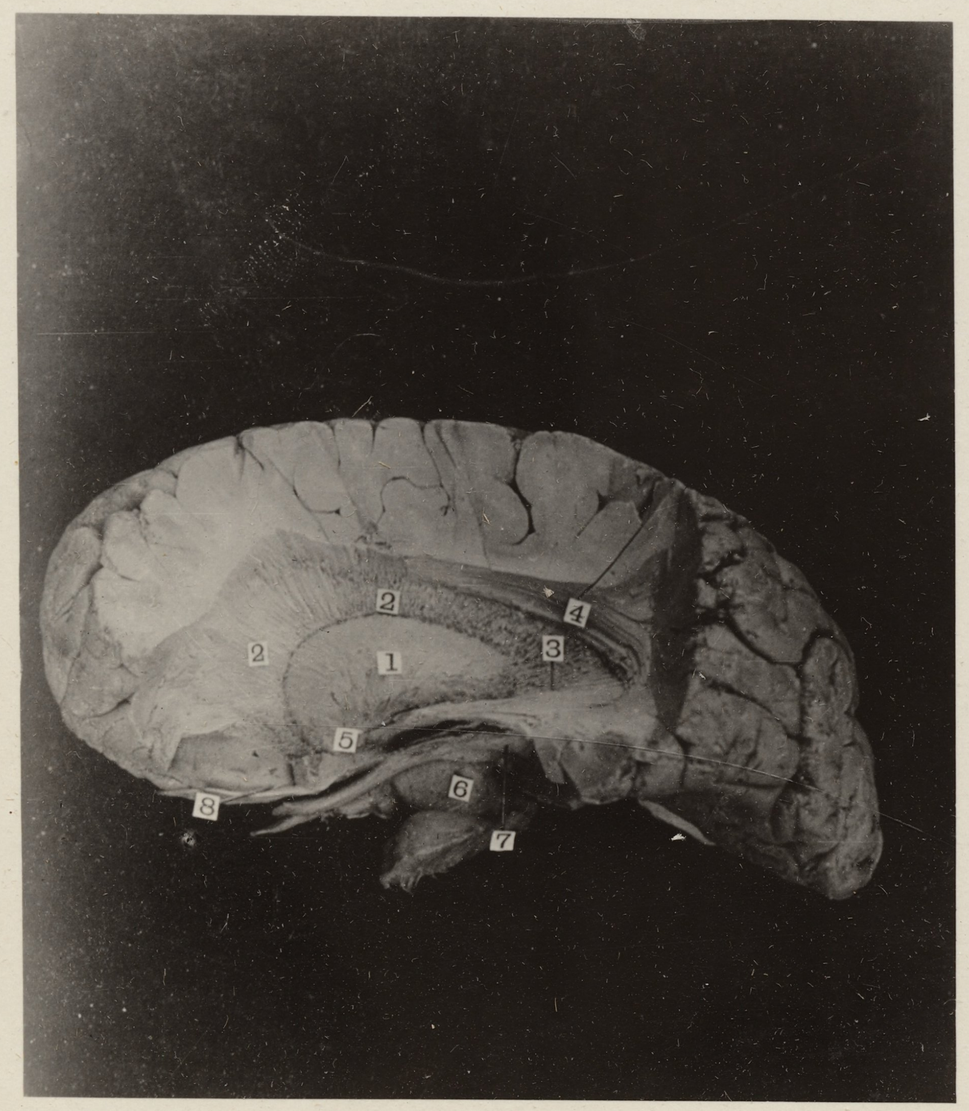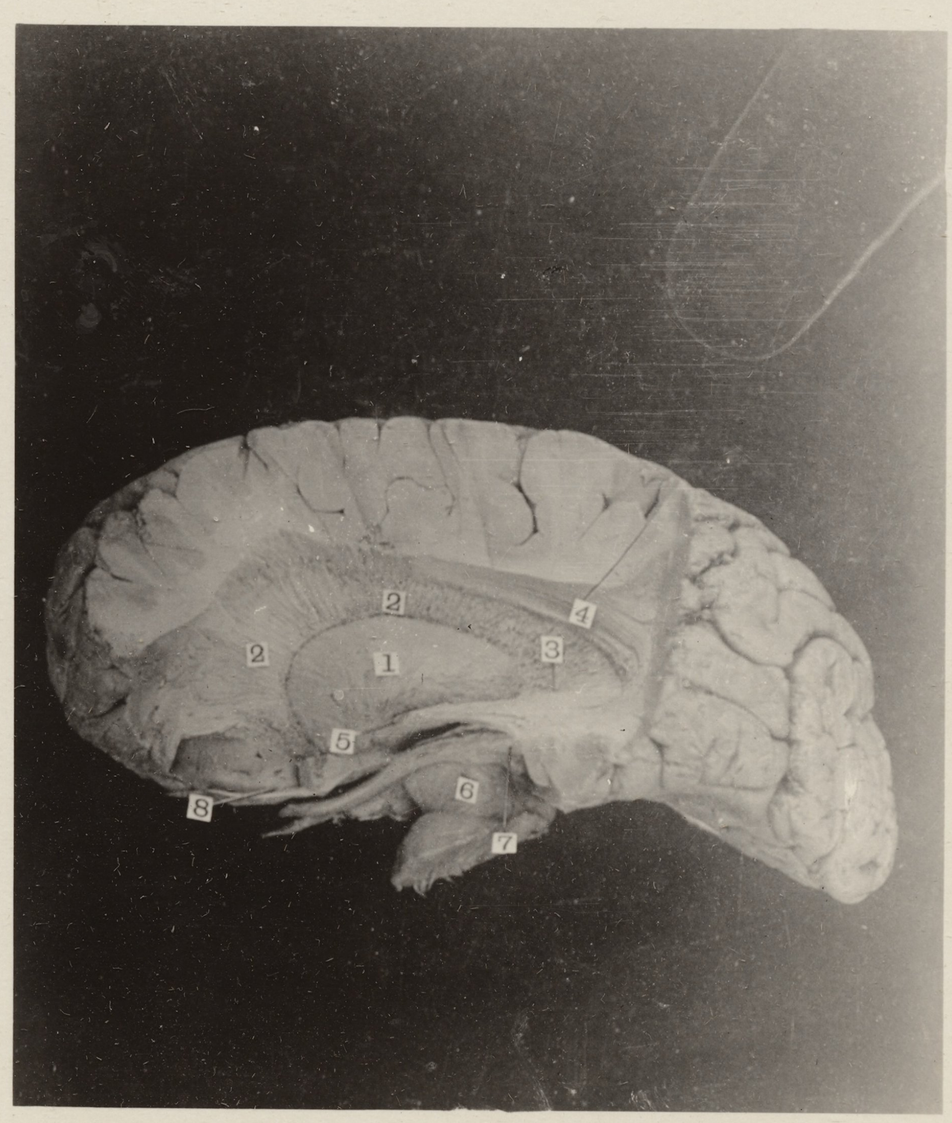
1. Lenticular nucleus.
2. Corona radiata.
3. Optic radiation.
4. Superior longitudinal fasciculus.
5. Anterior white commissure. Between the commissure and the optic radiation are temporo-pontine fibres and fibres of the auditory radiation.
6. Crusta of the mid-brain (crus cerebri).
7. External geniculate body.
8. Olfactory peduncle. Between the figure 5 and the optic tract is the anterior perforated spot.