CRANIO-CEREBRAL TOPOGRAPHY—No. 7.

THE RIGHT CEREBRAL HEMISPHERE HAS BEEN REMOVED, IN ORDER TO SHOW THE MEMBRANES WHICH SUB-DIVIDE THE CRANIAL CAVITY AND A PART OF THE MESIAL SURFACE OF THE HEMISPHERE OF THE OPPOSITE SIDE.

The **falx cerebri** is a sickle-shaped fold of dura mater, attached in front to the crista galli of the ethmoid and to the frontal bones, and attached behind to the upper surface of the tentorium cerebelli. It has an upper and a lower margin, the upper being convex and the lower concave.

The convex margin is attached along the mesial plane, and contains the superior longitudinal sinus, while the lower concave margin is free and overlies the corpus callosum. This edge contains the inferior longitudinal sinus.

The **tentorium cerebelli** is a sloping horizontal shelf which roofs over the cerebellum. It is crescentic in shape, and is attached behind and at the convex margin while the concave free margin limits, behind and at the sides, an oval aperture which transmits the mid-brain.

It is attached in front to the clinoid processes of the sphenoid bone, and externally to the upper border of the petrous temporal bone. The lateral sinus is contained along the line where the tentorium joins the general investing dura mater at the back and sides, over the mastoid portion of the temporal and along the occipital bone.

The section through the brain shows the third ventricle, and also the lateral ventricle of the opposite side, which has been exposed by the removal of the **septum lucidum.**

The figures indicate—
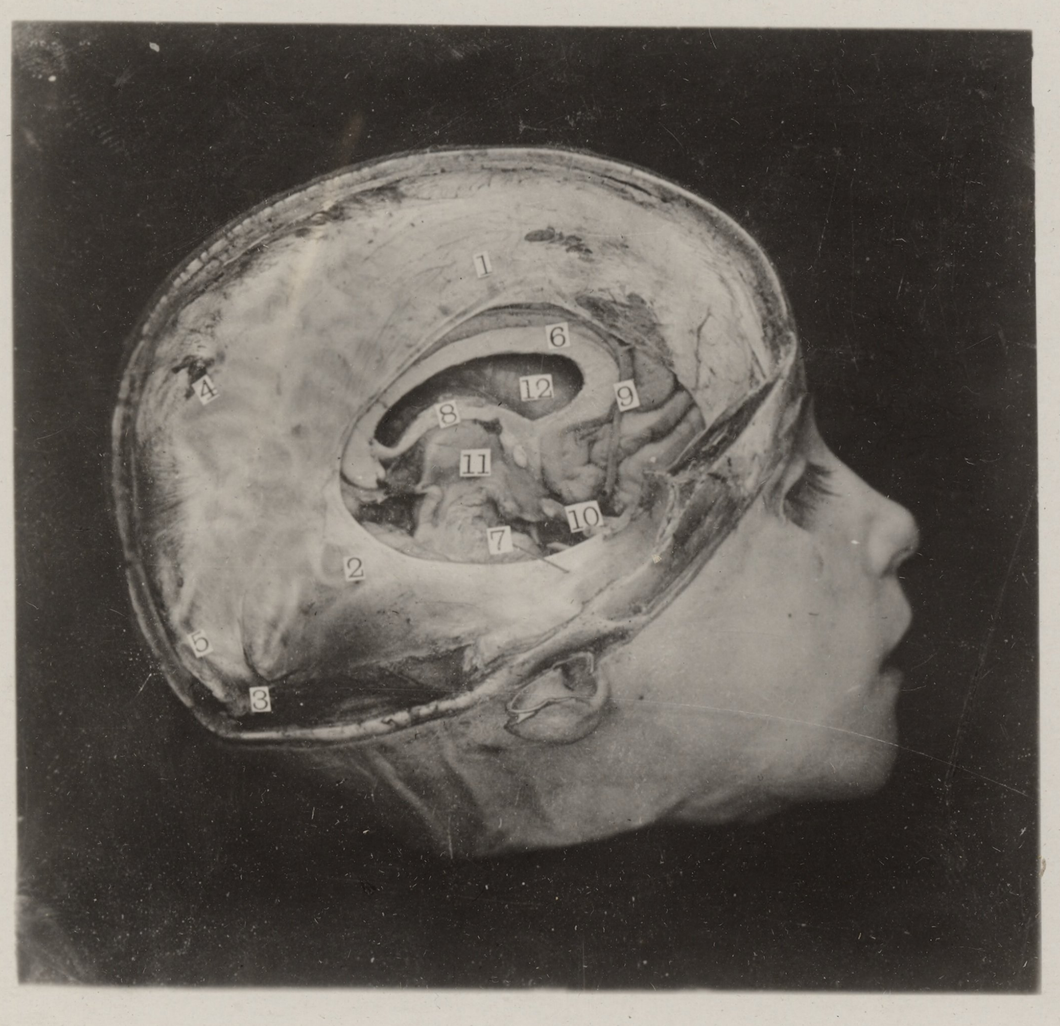
1. Falx cerebri.
2. Tentorium cerebelli.
3. Lateral sinus and cerebral vein.
4. Cerebral veins passing into superior longitudinal sinus.
5. Superior longitudinal sinus.
6. Corpus callosum.
7. Apex of petrous temporal bone.
8. Fornix.
9. Anterior cerebral artery.
10. Optic nerve, and middle cerebral artery.
11. Third ventricle.
12. Caudate nucleus of left side.